



HAL
open science

**A study of optic nerve head drusen in 38
pseudoxanthoma elasticum (PXE) patients (64 eyes).
Location of optic nerve head drusen in PXE**

V Pipelart, B Leroux, Stéphanie Leruez, Samir Henni, Nastassia Navasiolava,
Ludovic Martin, Jean-Marc Ebran

► **To cite this version:**

V Pipelart, B Leroux, Stéphanie Leruez, Samir Henni, Nastassia Navasiolava, et al.. A study of optic nerve head drusen in 38 pseudoxanthoma elasticum (PXE) patients (64 eyes). Location of optic nerve head drusen in PXE. *Journal Français d'Ophtalmologie*, 2019, 42 (3), pp.262-268. 10.1016/j.jfo.2018.08.007 . hal-02616933

HAL Id: hal-02616933

<https://univ-angers.hal.science/hal-02616933>

Submitted on 22 Oct 2021

HAL is a multi-disciplinary open access archive for the deposit and dissemination of scientific research documents, whether they are published or not. The documents may come from teaching and research institutions in France or abroad, or from public or private research centers.

L'archive ouverte pluridisciplinaire **HAL**, est destinée au dépôt et à la diffusion de documents scientifiques de niveau recherche, publiés ou non, émanant des établissements d'enseignement et de recherche français ou étrangers, des laboratoires publics ou privés.



Distributed under a Creative Commons Attribution - NonCommercial 4.0 International License

A Study of Optic Nerve Head Drusen in 38 Pseudoxanthoma Elasticum (PXE) Patients (64 eyes). Location of optic nerve head drusen in PXE

Etude des drusen du nerf optique dans le pseudoxanthome élastique chez 38 patients (PXE). Localisation des drusen du nerf optique dans le PXE.

PIPELART Valentin^{1*}, LEROUX Bastien¹, LERUEZ Stéphanie¹, HENNI Samir^{2,3},
NAVASIOLAVA Nastassia³, MARTIN Ludovic^{3,4}, EBRAN Jean-Marc^{1,3}

1. Department of Ophthalmology, Angers University Hospital, 2 rue Larrey 49933 Angers Cedex 9
2. Department of Vascular Function Investigation, Angers University Hospital
3. Pseudoxanthoma Elasticum Referral Centre, Angers University Hospital
4. Department of Dermatology, Angers University Hospital

*Correspondence:

PIPELART Valentin valentinpipelart@yahoo.fr

Service d'ophtalmologie – CHU – 2 rue Larrey 49933 Angers Cedex 9 (France)

Telephone: 00 33 (0)2 41 35 44 64 Fax: 00 33 (0)2 41 35 54 80

Abstract:

Purpose: To investigate the prevalence and location of optic nerve head drusen and their potential association with other PXE-related ophthalmic abnormalities.

Materials and Methods: 38 of the 155 patients (57 male and 98 female aged 49 ± 17 years) included in this retrospective study had optic nerve head drusen. All of the patients underwent a comprehensive ophthalmic examination, including color images using red-free, blue and red filters, autofluorescence imaging and late-phase ICG frames.

Comparative analysis of both groups (optic nerve head drusen or not) was conducted using R statistical software.

Results: The prevalence of optic nerve head drusen in our cohort was 24.5%. In this study, no evidence of a significant link between optic nerve head drusen and other fundus abnormalities was detected. They were more commonly located in the nasal sector than in the temporal sector of the optic disc ($p < 0.001$). They were more frequently situated superonasally than inferonasally ($p < 0.004$), superotemporally ($p < 0.001$) or inferotemporally ($p < 0.03$). No central visual field defect was observed in OND+ patients who were unaffected by macular disorders.

Discussion: We hypothesized this predominantly nasal primary location may result from greater sensitivity in the nasal optic nerve fibers which follow a much more angular path once they arrive in the scleral canal, accounting for accumulation of axoplasmic debris.

Conclusion: In PXE, optic nerve head drusen are mostly located in the superonasal quadrant, causing progressive optic nerve invasion but probably no central visual field defects.

Key-words: Pseudoxanthoma elasticum, calcification, Bruch's membrane, retinal pigment epithelium atrophy, optic nerve head drusen

Résumé :

Objectif : Etudier la prévalence, la localisation, et l'association éventuelle des drusen de la tête du nerf optique (DNO) aux autres anomalies ophtalmologiques dans le pseudoxanthome élastique

Matériels et méthodes : 38 des 155 patients (57 hommes et 98 femmes âgés de 49 ± 17 ans) inclus dans une étude rétrospective avaient des DNO. Tous les patients ont fait l'objet d'un examen ophtalmologique complet avec prise de clichés couleurs, en anérythre, en bleu, en rouge, en autofluorescence et en ICG avec clichés tardifs.

Une analyse de comparaison des 2 groupes DNO+ et DNO- a été exécutée sur le logiciel de statistique R.

Résultats : La prévalence des DNO dans notre cohorte est de 24.5%, Notre étude n'a pas mis en évidence d'association significative entre les DNO et les autres atteintes du fond d'œil. Les DNO étaient plus fréquemment localisés dans le secteur nasal que dans le secteur temporal de la papille ($p < 0.001$). Ils étaient plus fréquemment localisés dans le quadrant nasal supérieur que dans le quadrant nasal inférieur ($p < 0.004$), temporal supérieur ($p < 0.001$) ou temporal inférieur ($p < 0.03$). Aucun déficit central n'a été retrouvé sur le champ visuel des patients DNO+ indemne de maculopathie. Discussion : Cette localisation nasale débutante préférentielle pourrait être due à une sensibilité plus importante des fibres optiques nasales qui ont un trajet beaucoup plus coudé lors de leur arrivée dans le canal scléral, responsable d'une accumulation de déchets axoplasmiques.

Conclusion : Dans le PXE les DNO sont localisés de façon préférentielle dans le cadran nasal supérieur, avec un envahissement progressif du nerf optique mais probablement sans répercussion sur le champ visuel central.

Mots clefs: Pseudoxanthome élastique; calcification; membrane de Bruch; atrophie épithélium pigmentaire; drusen du nerf optique

Introduction:

Optic nerve drusen (OND) are calcium deposits located within the optic nerve . When anterior, they are visible in the fundus and/or revealed by autofluorescence imaging, or they may be situated in a more posterior position and are consequently only visible by means of B-scan ultrasonography or ultimately CT scan. In the general population, prevalence of drusen is 2% [1,2] with no sex predilection [3]. Drusen are usually asymptomatic and are detected incidentally during routine ophthalmic examination. They are found in the fundus in the shape of crystalline structures embedded within the optic nerve head, giving the optic disc an appearance evocative of papilloedema [4].

PXE is a genetic disorder caused by mutation in both alleles of the *ABCC6* gene located on chromosome 16p13.1. It is characterised by calcification of connective tissue in the skin, arterial walls and Bruch's membrane of the choroid.

The aim of this study is to investigate the prevalence and location of optic nerve head drusen and their potential association with other fundus abnormalities in PXE patients, and to compare two patient groups: one with optic nerve drusen (OND+) and the other without drusen (OND-).

Materials and Methods:

The patients included in this study were part of a retrospective database comprising each of the PXE patients examined at a national referral centre within the framework of multidisciplinary PXE consultation between 2008 and 2017.

All of the patients presented with PXE confirmed by histopathological findings based on skin biopsies and/or evidence of *ABCC6* gene mutations. Patients whose diagnostic confirmation was impossible were systematically excluded from the trial. Data from ophthalmoscopy findings accessible as photographic documents were reviewed retrospectively. The study was conducted in line with the ethical principles of the Declaration of Helsinki. All of the patients involved provided consent for participation in the study.

The patients underwent a clinical examination involving: measurement of best-corrected visual acuity in each eye; determination of intraocular pressure; recording in fully dilated eyes of colour images of the macula (non-mydratic retinal camera TRC-NW6S Topcon Japan); red-free images of the macula and the entire retinal periphery; and blue, red and autofluorescence images of the macula (retinal camera TRC-50IX Topcon Japan and F-10 ophthalmoscope Nidek Japan). Indocyanine green (ICG) angiography was performed on the vast majority of these patients, using the aforementioned equipment, to test the late-phase cyanescence of potential streaks.

The database was implemented in Excel and the statistical operations were performed using R statistical software. Descriptive statistical analysis was performed on quantitative variables (mean, standard deviation, median, minimum, maximum) and on qualitative variables (counts and percentages). Fisher's exact test was used for qualitative variables and Kruskal-Wallis tests were used for quantitative variables. Exploratory univariate analysis was performed so as to elucidate possible correlation between evidence of OND and certain demographic variables (sex or age), genotypes or specific clinical manifestations (peau d'orange, comet tail lesions, pattern dystrophy, subretinal fibrosis, age at onset of initial neovascular complication, late-phase hyper or hypocyancescence of angioid streaks on ICG images, ,), and macular disorders (which we judged to be incapacitating where visual acuity was equal to 4/10 or less).

Visual field impairment was investigated using perimetry and patients suffering from incapacitating maculopathy were excluded to facilitate the comparison between the two groups and determine the various types of impairment related to OND.

Supposing a hypothetical correlation between genotype and phenotype, we attempted to establish a connection between the most common ABCC6 mutations and OND. DNA derived from peripheral blood was analysed using specific kits: the High pure PCR Template Preparation Kit (Roche Applied Sciences, Mannheim, Germany) and the genomic DNA purification kit (Quick-gDNA MiniPrep-D3024, Zymo Research, Freiburg, Germany), or the QIAamp DNA Mini Kit with the QIAcube robotic station (Qiagen, Hilden, Germany).

Genetic analysis was carried out in three stages: first, analysis of molecular hotspots (search for mutations in exons 18, 24, 28, 29 and search for del23-29 multi exon deletion); in the absence of mutation, whole coding region analysis of the ABCC6 gene was then conducted using PCR and direct sequencing. Where there was still no evidence of mutation, a third analysis was carried out using multiplex ligation-dependent probe amplification (MLPA). [5]

Results:

Out of a database of 182 patients, 6 patients presenting with positive skin biopsy but no manifestation of fundus disease were excluded as were 21 other patients due to ambiguous diagnosis of PXE.

This study therefore reviewed 155 patients suffering from PXE, of which 36.8% were male and 63.2% female, aged from 10 to 83 years (mean 49 ± 17 years). Among these 155 patients, 38 exhibited optic nerve head drusen (24.5%) which were unilateral in 31.5% of cases and bilateral in 68.5% of cases, amounting to a total of 64 eyes. There was no statistically significant difference in male/female distribution between the drusen group (36% males, 64% females) and the total number of PXE

patients (37% males, 63% females). No statistically significant difference was detected between the two groups in terms of patient age, spherical equivalent, axial length and mean keratometry.

A / Associations between the various lesions

Findings are shown in Tables 1 and 2.

No statistically significant difference was found between the two groups in terms of peau d'orange ($p = 0.774$), comet tail lesions ($p = 0.32$), primary macular dystrophy ($p = 1$), previous history of subretinal neovascularisation ($p = 1$), incapacitating maculopathy ($p = 0.064$), subretinal fibrosis ($p = 0.584$), and evidence of hypercyanescent ($p = 0.864$) or hypocyanescent ($p = 0.8596$) streaks on late-phase ICG angiography.

Optical fibre layer thickness was significantly poorer in patients affected by drusen than in the control group ($p=0.00397$). This variation occurred more often in the superior ($p = 0.00078$) and nasal ($p = 0.0015$) fibre sectors than in the inferior fibre sectors ($p = 0.032$). It was not detected in the temporal sectors ($p=0.2052$).

B / Parametric visual field analysis

We also analysed patients with parametric visual field impairment (automated 24.2 VF deficit with reduction in mean deviation MD) but unaffected by any other form of maculopathy, on a total of 55 eyes. Evidence of drusen was not statistically associated with a higher rate of visual field defects ($p=0.3079$).

The most common visual field deficits detected were nerve fibre bundle defects, nasal step and blind spot enlargement. There was no central impairment.

C/ Analysis of drusen size and location

Findings are shown in Tables 3, 4 and 5.

Analysis was conducted on autofluorescence images, which were available for 60 eyes out of 64 (autofluorescence images were lacking in 3 patients, of whom 2 sustained unilateral damage and 1 bilateral damage). Drusen were located superonasally in 51/60 eyes (85%), inferonasally in 24/60 eyes (40%), inferotemporally in 15/60 eyes (25%) and superotemporally in 11/60 eyes (18.3%).

Some drusen extended into several adjacent quadrants, explaining why the sum of the 4 quadrants exceeded 100%. Drusen size was analysed using a 3 category classification system based on data provided by autofluorescence imaging:

- small: <1/3 of the optic disc surface area (Figure 1);
- intermediate: between 1/3 and 2/3 of the optic disc surface area (Figure 2);
- large: >2/3 of the optic disc surface area (Figure 3).

In this study, 31 small drusen (stage 1) were found in 51.7% of patients, 13 intermediate drusen (stage 2) were found in 21.7% of patients and 16 large drusen (stage 3) were found in 26.6% of patients. (Table 3).

Stage 1 drusen: 23/31 stage 1 drusen (74.2%) were located in the superonasal quadrant of the papilla, 6/31 (19.3%) in the inferotemporal quadrant, and 2/31 (6.5%) in the inferonasal quadrant, amounting to a total of 80.7% in the nasal and 19.3% in the temporal quadrants. Stage 2 drusen: the 13 stage 2 drusen (100%) were situated in the superonasal or inferonasal quadrant. Stage 3 drusen: 15 of the 16 stage 3 drusen, (93.75%) were situated in the superonasal sector, 12/16 in the inferonasal sector (75%), 11/16 in the superotemporal sector (68.75%) and 9/16 in the inferotemporal sector (56.25%). In total, drusen were detected in the nasal sector in 90% of cases and in the temporal sector in 36.6%.

According to findings from post hoc significance analysis, optic nerve head drusen were more commonly found in the nasal sector of the papilla than in the temporal sector ($p < 0.001$). They were more frequently located in the superonasal quadrant than in the inferonasal ($p < 0.004$), superotemporal ($p < 0.001$) and inferotemporal ($p < 0.03$) quadrants.

Correlation analysis demonstrated negative correlation between drusen size and mean optical fibre layer thickness (Spearman correlation coefficient: -0.655 with a p-value of $p < 0.001$). Retinal nerve fibre layer (RNFL) thickness was inversely proportional to drusen size.

D/ Genotype analysis

The ABCC6 genotype was also analysed across both groups. A genotype was identified in 35/38 patients from the drusen group and in 83/117 patients from the control group.

The five most common mutations detected were as follows: p.Arg1141Ter, p.Glu1400Lys, Del 23-29, p.Arg1164Ter and p.Arg518Gln.

- the p.Arg1141Ter mutation was found in 7 patients from the drusen + group and 32 patients from the drusen - group, demonstrating a trend towards significance between the two groups ($p = 0.056$)
- the p.Glu1400Lys mutation was not found in any patients from the drusen + group and was found in 5 patients from the drusen - group ($p = 0.3209$)

- the Del 23-29 mutation was found in 8 patients from the drusen + group and 4 patients from the drusen - group ($p=0.7478$)
- the p.Arg1164Ter mutation was found in 1 patient from the drusen + group and 3 patients from the drusen - group ($p=1$)
- the p.Arg518Gln mutation was not found in any patients from the drusen + group and was found in 5 patients from the drusen - group ($p=0.319$)

Discussion

Prevalence of optic nerve head drusen (OND) in our cohort was 24.5%, consistent with Pierro et al, whose study revealed 21.6% of OND on B-scan ultrasonography in 58 patients with angioid streaks. [6].

Our findings innovatively demonstrate that the most common location of optic nerve head drusen in PXE is in the nasal sector. This location was apparent in 80.7% of patients with small drusen and in 100% of patients with intermediate or large drusen (Figure 3, Table 3). Overall, 90% of drusen were situated in the nasal quadrants of the papilla. To our knowledge, predominance of this location has not been previously reported in the literature.

However, our study failed to identify any significant correlation between OND and other fundus disorders in PXE. There was no evidence of significant difference in ocular biometric characteristics between the two groups (i.e. age, spherical equivalent, axial length, mean keratometry). This nasal location can explain the same visual acuity between DNO+ and DNO-, because the temporal sector is rarely affected by the DNO.

In the general population, several pathophysiological hypotheses regarding the onset of OND have been described. Drusen are believed to occur as a consequence of axoplasmic flow disturbance in the optic nerve head [7]. They accumulate in the cribriform plate and over time cause optic nerve head deformation. The notion of a narrow scleral canal features prominently as a pathophysiological hypothesis in the literature. It is thought that axoplasmic debris remains trapped above the scleral canal which acts as a bottleneck [8]. A recent study based on OCT examination found no significant difference in scleral canal size between patients from the OND+ and the OND- group [9]. We were unable to test this hypothesis in our cohort but more detailed examination of the scleral canal using latest generation OCT imaging could provide relevant findings.

The hypothesis that autosomal dominant transmission with incomplete penetrance accounts for onset of OND has been evoked by Lorentzen [3]. There are however

many sporadic forms. The familial nature of certain OND is believed to be linked to vascular nerve head abnormalities [10,11,12]. Our study failed to establish a relationship between any of the common mutations of the *ABCC6* gene and OND. In the course of PXE, no evidence of genotypic/phenotypic correlation has ever been substantiated [13].

Ethnic origin may also constitute a risk factor, since incidence of OND in the African-American population is reportedly lower [14]. This article highlights a greater cup-to-disc ratio in the African-American population than in the Caucasian population.

OND can be complicated by acute non-arteritic anterior ischemic optic neuropathy (NAION) involving direct compression of the papillary vasculature [15]. Kapur et al have proven the calcium phosphate ($Ca_3(PO_4)_2$) characteristics of OND in the general population using spectroscopic analysis [16]. None of the patients in our cohort experienced NAION. In PXE, OND conceivably result from direct calcification of the optic nerve cribriform plate involving axoplasmic flow disturbance.

Out of the 31 small drusen, 23 were superonasal to the papilla, and can be attributed to initial impairment on the nasal side spreading progressively to the whole optic disc, and thus ultimately affecting the temporal sector. We formulate the hypothesis that this primary predominantly nasal location could be caused by greater sensitivity in the nasal optical fibres which follow a much more angular path once they arrive in the scleral canal. It is thought that those fibres having a sharper angle of intrascleral penetration are compressed, resulting in disturbance to the flow of axoplasmic metabolites and their excessive accumulation in the nasal area of the papilla.

Serious attenuation of nerve fibre layer thickness may occur as a consequence of compressive damage to the nerve fibres caused by OND, involving sequelar atrophy which accounts for reduced fibre thickness. Given that this damage is situated in exactly the same location as the drusen, we suggest that it is the drusen that are responsible for in situ atrophy of the nerve fibres. Retinal nerve fibre layer (RNFL) thickness is inversely proportional to drusen size. This finding is corroborated by Skaat et al who found a correlation between drusen size and structural/functional damage to the optic nerve in 47 eyes affected by OND [17].

The visual field defects detected in the course of PXE were typically nerve bundle defects, nasal step and blind spot enlargement. The extreme peripheral visual field defects are not necessarily detected with a 24.2 automatic visual fields.

The central defects apparent in our study bore no relation to OND and were more suggestive of underlying macular disease (exudative disorders, pattern dystrophy, angioid streaks with macular involvement), as reported by Lee who found no evidence of central deficit in a cohort of patients affected by OND with no other concomitant abnormalities [18].

The new imaging modalities of enhanced depth imaging optical coherence tomography (EDI-OCT) and swept source optical coherence tomography (SS-OCT) are new “gold standard” for detecting OND. A study with these techniques will be interesting.

Conclusion

Prevalence of 24.5% of OND in PXE with primary incidence in the superonasal area can be attributed to direct calcification of the cribriform plate in addition probably to a more angular path of the nasal nerve fibres, accounting for axoplasmic debris in the nasal sector of the papilla which progressively spreads to the entire optic disc, ultimately affecting the temporal area.

Screening for optic nerve drusen should be mandatory in the event of any peripheral visual field defect in PXE patients. Conversely, any central defect should lead to screening for another cause such as exudative maculopathy, which does not bode well for favourable ocular outcomes in these patients.

Disclosure of interest

The authors declare that they have no conflict of interest concerning this article

References:

- 1/ Auw-Haedrich C, Staubach F, Witschel H. Optic disk drusen. *Surv Ophthalmol.* 2002 Nov-Dec;47(6):515-32.
- 2/ Friedman AH, Beckerman B, Gold DH, Walsh JB, Gartner S Drusen of the optic disc. *Surv Ophthalmol.* 1977 Mar-Apr;21(5):373-90.
- 3/ You QS, Xu L, Wang YX, Jonas J Prevalence of optic disc drusen in an adult Chinese population: the Beijing Eye Study. *Acta Ophthalmol.* 2009 Mar;87(2):227-8. doi: 10.1111/j.1755-3768.2008.01211.x. Epub 2008 Jun 2.
- 4/ Khonsari RH1, Wegener M, Leruez S, Cochereau I, Milea D[Optic disc drusen or true papilledema?]. *Rev Neurol (Paris).* 2010 Jan;166(1):32-8. doi: 10.1016/j.neurol.2009.05.003. Epub 2009 Jun 21.
- 5/ Hosen MJ, Van Nieuwerburgh F, Steyaert W, Deforce D, Martin L, Leftheriotis G, De Paepe A, Coucke PJ, Vanakker OM. Efficiency of exome sequencing for the molecular diagnosis of pseudoxanthoma elasticum. *J Invest Dermatol.* 2015 Apr;135(4):992-998. doi: 10.1038/jid.2014.421.
- 6/ Pierro L, Brancato R, Minicucci M, Pece Echographic diagnosis of Drusen of the optic nerve head in patients with angioid streaks. *Ophthalmologica.* 1994;208(5):239-42.
- 7/ Spencer WH. Drusen of the optic disk and aberrant axoplasmic transport. The XXXIV Edward Jackson memorial lecture. *Am J Ophthalmol.* 1978 Jan;85(1):1-12.
- 8/ Jonas JB, Gusek GC, Guggenmoos-Holzmann I, Naumann GO. Optic nerve head drusen associated with abnormally small optic discs. *Int Ophthalmol.* 1987 Dec;11(2):79-82.
- 9/ Floyd MS1, Katz BJ, Digre KB. Measurement of the scleral canal using optical coherence tomography in patients with optic nerve drusen. *Am J Ophthalmol.* 2005 Apr;139(4):664-9.
- 10/ Antcliff RJ, Spalton DJ. Are optic disc drusen inherited? *Ophthalmology.* 1999 Jul;106(7):1278-81.
- 11/ Lorentzen SE. Drusen of the optic disk. A clinical and genetic study. *Acta Ophthalmol (Copenh).* 1966:Suppl 90:1-180.
- 12/ Sacks JG, O'Grady RB, Choromokos E, Leestma J. The pathogenesis of optic nerve drusen. A hypothesis. *Arch Ophthalmol.* 1977 Mar;95(3):425-8.
- 13/ Pfindner EG1, Vanakker OM, Mutation detection in the ABCC6 gene and genotype-phenotype analysis in a large international case series affected by pseudoxanthoma elasticum. *J Med Genet.* 2007 Oct;44(10):621-8. Epub 2007 Jul 6

- 14/ Thurtell MJ, Biousse V, Bruce BB, Newman NJ. Optic nerve head drusen in black patients. *J Neuroophthalmol.* 2012 Mar;32(1):13-6.
- 15/ Purvin V, King R, Kawasaki A, Yee R. Anterior ischemic optic neuropathy in eyes with optic disc drusen. *Arch Ophthalmol.* 2004 Jan;122(1):48-53.
- 16/ Kapur R1, Pulido JS, Abraham JL, Sharma M, Buerk B, Edward DP. Histologic findings after surgical excision of optic nerve head drusen. *Retina.* 2008 Jan;28(1):143-6. doi: 10.1097/IAE.0b013e31815e98d8.
- 17/ Skaat A1,2, Muylaert S1, Mogil RS3,4, Furlanetto RL1, Netto CF1, Banik R1,5, Liebmann JM6, Ritch R1, Park SC3,4. Relationship Between Optic Nerve Head Drusen Volume and Structural and Functional Optic Nerve Damage. *J Glaucoma.* 2017 Dec;26(12):1095-1100.
- 18/ Lee AG, Zimmerman MB. The rate of visual field loss in optic nerve head drusen. *Am J Ophthalmol.* 2005 Jun;139(6):1062-6.

Legends table and figure:

FIGURE 1 Optic nerve head drusen stage 1.

FIGURE 2 Optic nerve head drusen stage 2.

FIGURE 3 Optic nerve head drusen stage 3.

		Drusen ON	Drusen OFF	Statistical significanc : p
Gender	Homme	23(35.94%)	91(36.99%)	1
	Femme	41(64,06%)	155(63%)	
Maculopathy	n	34	97	0.06446
	%	53,13%	39,43%	
Angioïdes streaks	n	63	233	0.3149
	%	98,44%	94,72%	
Peau d'orange	n	40	144	0.7744
	%	62,50%	58,54%	
Comet tail	n	40	130	0.3205
	%	62,50%	52,85%	
Subretinal fibrosis	n	5	15	0.5842
	%	7,81%	1,56%	
Subretinal neovascularisation	n	2	9	1
	%	3,13%	3,66%	
Primary macular dystrophy	n	5	20	1
	%	7,81%	8,13%	
Angioïdes streaks hyperfluorescent	n	16	59	0.8645
	%	25,00%	23,98%	
Angioïdes streaks hypofluorescent	n	36	135	0.8596
	%	56,25%	54,88%	
Parametric visual field impairment	n	16	39	0.09919
	%	25,00%	15,85%	

Table 1 Study the association between the presence or not optic nerve head drusen and the qualitative variables.

	Mean		Statistically significant p :
	Drusen ON	Drusen OFF	
Age	51,5	48,0813	0,1404
Visual acuity (without maculopathy)	9.5/10 P2	9.76/10 P2	1
LA	24,45656	23,73845	0,6267
KER	42,95164	43,53143	0,7811
ES	-0,8984375	-1,0598361	0,9754
RNFLM	84,44068	91,38356	0,00397
Nasal	65,40678	69,96804	0,001546
Temporal	68,42373	67,27854	0,2052
Superior	97,55932	112,27397	0,0007778
Inferior	106,4576	116,516	0,03224

Table 2: Study the difference between the two groups on the quantitative values, with the significance for each parameter.

	Nasal supérieur	Nasal inférieur	Temporal supérieur	Temporal e inferior	Nasal	Temporal	Total
Stage 1	23 (74.2%)	2 (6.5%)	0	6 (19.3%)	25 (80.7%)	6 (19.3%)	31 (51.66%)
Stage 2	13 (100%)	10 (77%)	0	0	13 (100%)	0	13 (21.66%)
Stage 3	15 (93.75%)	12 (75%)	11 (68.75%)	9 (56.25%)	16 (100%)	16 (100%)	16 (26.76%)
Total	51 (85%)	24 (40%)	11 (18.33%)	15 (25%)	54 (90%)	22 (36.6%)	60 (100%)

Table 3: Distribution in number and percentage of Drusen by papillary area according to size.

	Nasal	Temporal	p
Stage 1	25 (80.7%)	6 (19.3%)	<0.001
Stage 2	13 (100%)	0	
Stage 3	16 (100%)	16 (100%)	

Table 4 : Distribution the nasal or temporal location of the Drusen optic nerve.

Stage	NS	TI	p
Stage 1	23	6	0.03
Stage 2	13	0	
Stage 3	15	9	

Stage	NS	TS	p
Stage 1	23	0	<0.001
Stage 2	13	0	
Stage 3	15	11	

Stage	NS	NI	p
Stage 1	23	2	0.004
Stage 2	13	10	
Stage 3	15	12	

Table 5: Study the superior nasal location versus the other quadrants of the optic nerve

NS : Nasal supérieur ; TS : Temporal supérieur ; NI : Nasal inférieur

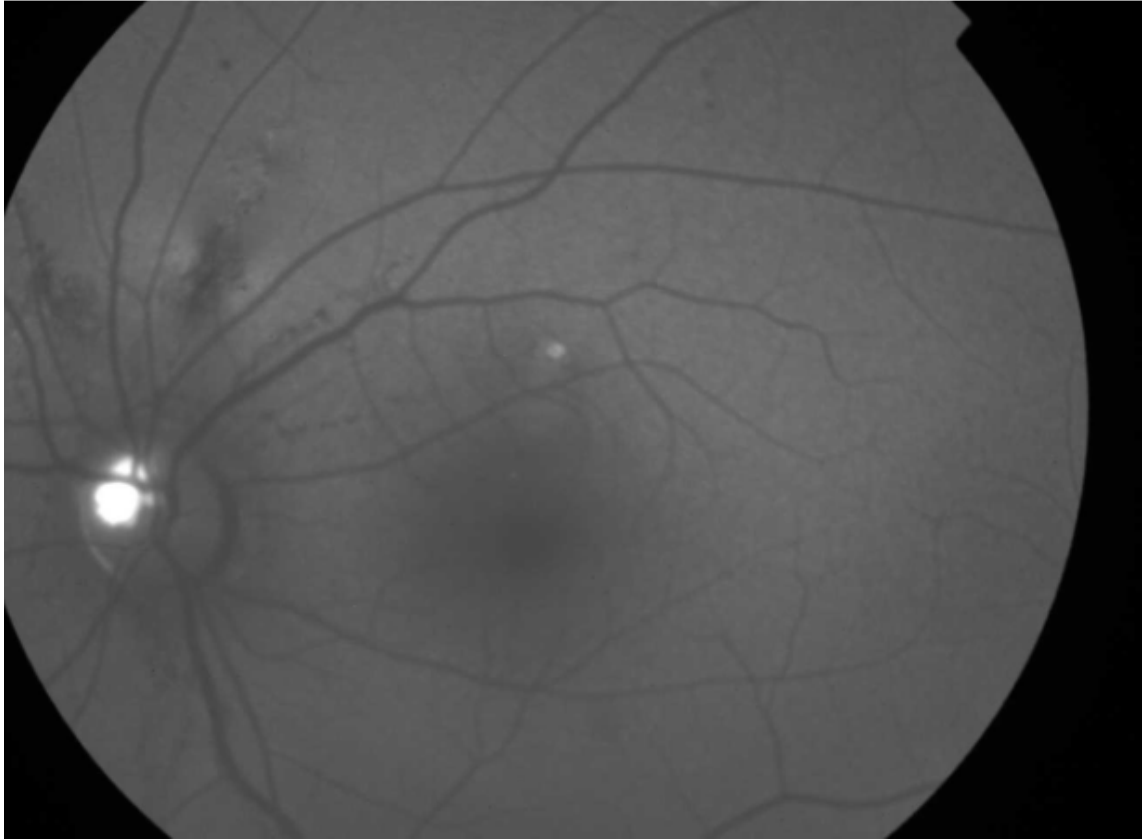


Figure 1: stage 1 drusen

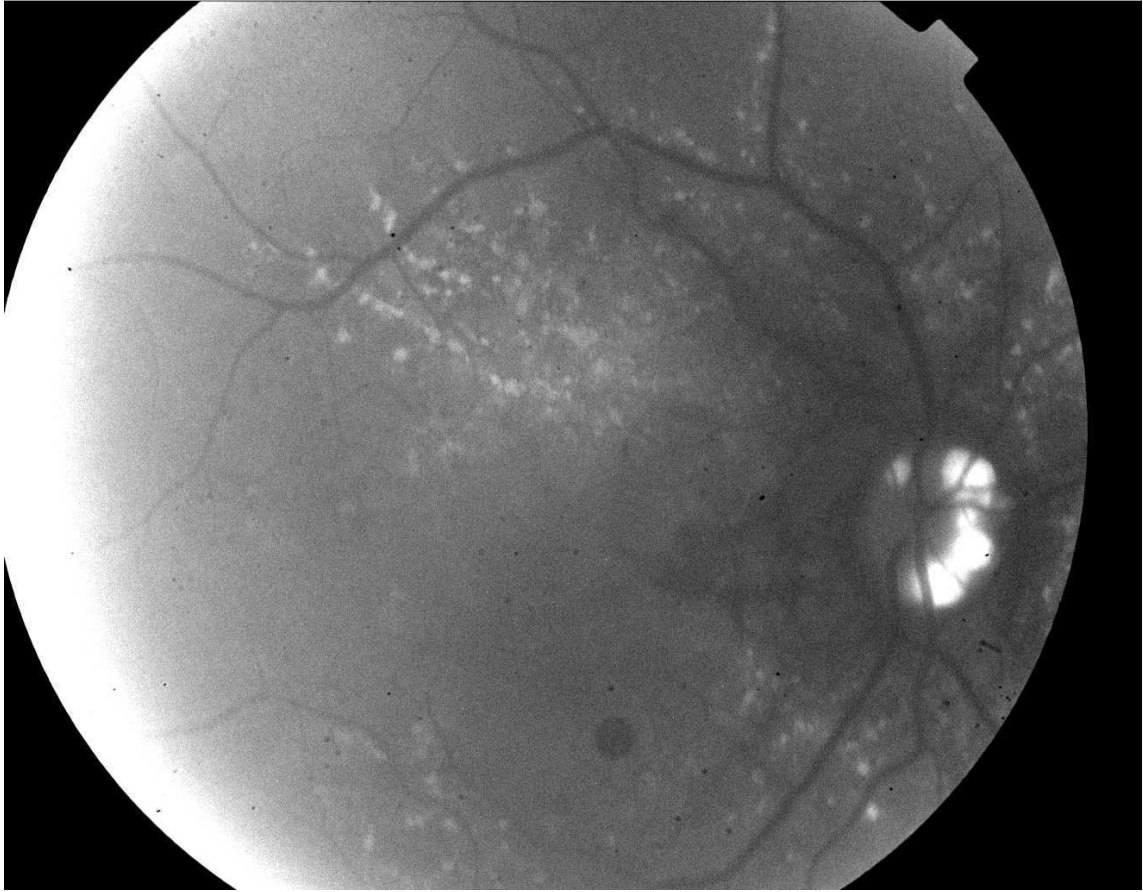

Figure 2: stage 2 drusen

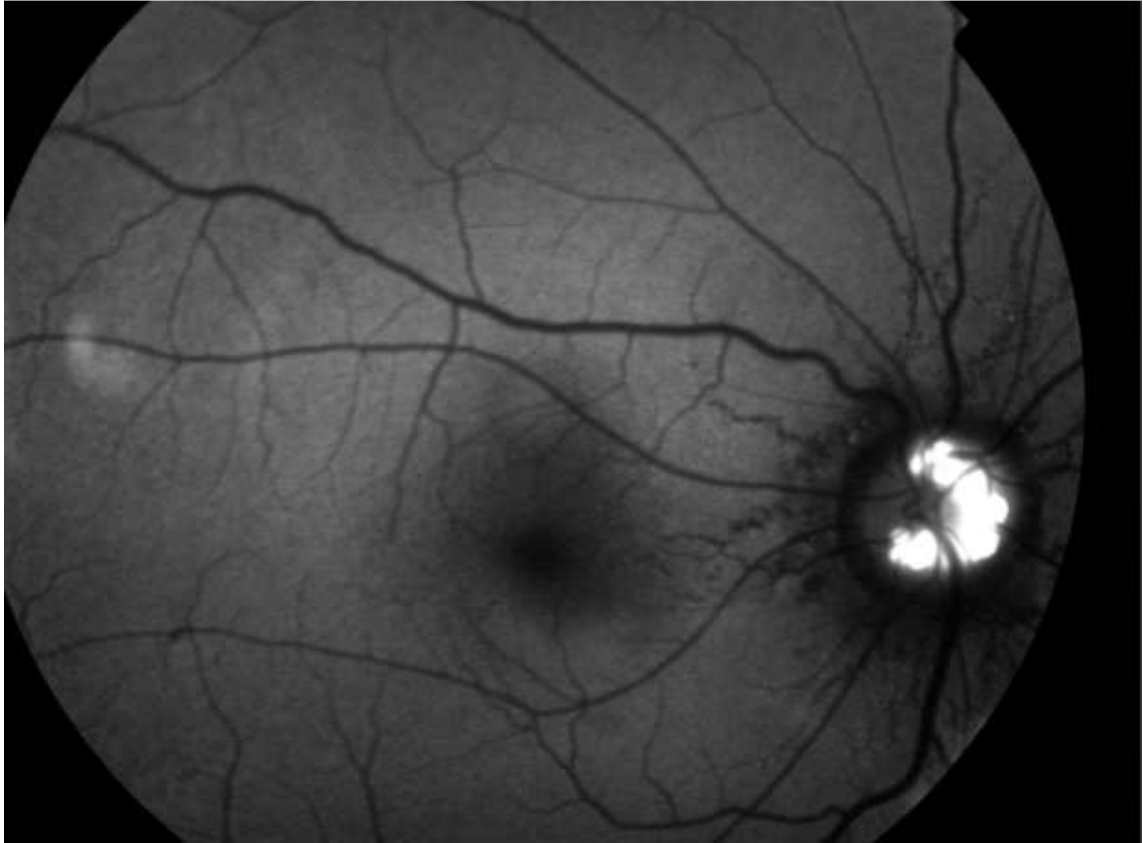


Figure 3: stage 3 drusen