



# Phenotypic spectrum associated with SPECC1L pathogenic variants: new families and critical review of the nosology of Teebi, Opitz GBBB, and Baraitser-Winter syndromes

Elizabeth Bhoj, Damien Haye, Annick Toutain, Dominique Bonneau, Irene Kibæk Nielsen, Ida Bay Lund, Pauline Bogaard, Stine Leenskjold, Kadri Karaer, Katherine Wild, et al.

## ► To cite this version:

Elizabeth Bhoj, Damien Haye, Annick Toutain, Dominique Bonneau, Irene Kibæk Nielsen, et al.. Phenotypic spectrum associated with SPECC1L pathogenic variants: new families and critical review of the nosology of Teebi, Opitz GBBB, and Baraitser-Winter syndromes. Eur J Med Genet, 2019, 62 (12), pp.103588. 10.1016/j.ejmg.2018.11.022 . hal-02616925

**HAL Id: hal-02616925**

**<https://univ-angers.hal.science/hal-02616925>**

Submitted on 21 Jul 2022

**HAL** is a multi-disciplinary open access archive for the deposit and dissemination of scientific research documents, whether they are published or not. The documents may come from teaching and research institutions in France or abroad, or from public or private research centers.

L'archive ouverte pluridisciplinaire **HAL**, est destinée au dépôt et à la diffusion de documents scientifiques de niveau recherche, publiés ou non, émanant des établissements d'enseignement et de recherche français ou étrangers, des laboratoires publics ou privés.



Distributed under a Creative Commons Attribution - NonCommercial 4.0 International License

# Phenotypic spectrum associated with *SPECC1L* pathogenic variants: new families and critical review of the nosology of Teebi, Opitz GBBB, and Baraitser-Winter syndromes

Elizabeth J. Bhoj<sup>1,2</sup>, Damien Haye<sup>3</sup>, Annick Toutain<sup>4</sup>, Dominique Bonneau<sup>5</sup>, Irene Kibæk Nielsen<sup>6</sup>, Ida Bay Lund<sup>6</sup>, Pauline Bogaard<sup>7</sup>, Stine Leenskjold<sup>8</sup>, Kadri Karaer<sup>9</sup>, Katherine T Wild<sup>1</sup>, Katheryn L Grand<sup>1</sup>, Mirena C. Astiazaran<sup>10</sup>, Luis A. Gonzalez-Nieto<sup>10</sup>, Ana Carvalho<sup>11</sup>, Daphné Lehalle<sup>12</sup>, Shivarajan M Amudhavalli<sup>13</sup>, Elena Repnikova<sup>14</sup>, Carol Saunders<sup>14</sup>, Isabelle Thiffault<sup>14</sup>, Irfan Saadi<sup>15</sup>, Dong Li<sup>2</sup>, Hakon Hakonarson<sup>2</sup>, Yoann Vial<sup>3</sup>, Elaine Zackai<sup>1</sup>, Patrick Callier<sup>11</sup>, Séverine Drunat<sup>3</sup>, Alain Verloes<sup>3</sup>

1. Department of Genetics, Children's Hospital of Philadelphia
2. Center for Applied Genomics, Children's Hospital of Philadelphia, Philadelphia, PA, United States;
3. Department of Genetics, APHP-Robert DEBRE University Hospital, Sorbonne Paris-Cité University, and INSERM UMR 1141, Paris
4. Bretonneau University Hospital, Tours
5. Department of Biochemistry and Genetics, and UMR CNRS 6015 INSERM 1083, University Hospital, Angers, France
6. Department of Clinical Genetics,
7. Department of Pathology, and
8. Department of Gynecology and Obstetrics, Aalborg University Hospital, Aalborg, Denmark;
9. Dr Ersin Arslan Research and Training Hospital, Department Of Medical Genetics, Gaziantep, Turkey
10. Genetics Department, Research Unit-Genetics Department, Institute of Ophthalmology, Conde de Valenciana, Mexico City, Mexico.
11. Clinical Genetics Department, Coimbra Paediatric Hospital, Coimbra PORTUGAL
12. Children University Hospital, Dijon, France;
13. Division of Clinical Genetics, Children's Mercy Hospital, University of Missouri Kansas City, School of Medicine, Kansas City, MO, United States
14. Center for Pediatric Genomic Medicine, Department of Pathology and Laboratory Medicine, Children's Mercy Hospital, University of Missouri Kansas City, School of Medicine, Kansas City, MO, United States
15. Department of Anatomy and Cell Biology, University of Kansas Medical Center, Kansas City, KS, United States

Address requests to Pr Alain Verloes, département de Génétique, Hôpital Robert Debré, 48 bd Sérurier, 75019 Paris, France. E-mail : [alain.verloes@aphp.fr](mailto:alain.verloes@aphp.fr)

## Running title

*SPECC1L* syndrome

## Abstract

The *SPECC1L* protein plays a role in adherens junctions involved in cell adhesion, actin cytoskeleton organization, microtubule stabilization, spindle organization and cytokinesis. It modulates PI3K-AKT signaling and controls cranial neural crest cell delamination during facial morphogenesis. *SPECC1L* causative variants were first identified in individuals with oblique facial clefts. Recently, causative variants in *SPECC1L* were reported in a pedigree reported in 1988 as atypical Opitz GBBB syndrome. Six families with *SPECC1L* variants have been reported thus far. We report here eight further pedigrees with *SPECC1L* variants, including a three-generation family, and a further individual of a previously published family. We discuss the nosology of Teebi and GBBB, and the syndromes related to *SPECC1L* variants. Although the phenotype of individuals with *SPECC1L* mutations shows overlap with Opitz syndrome in its craniofacial anomalies, the canonical laryngeal malformations and male genital anomalies are not observed. Instead, individuals with *SPECC1L* variants have branchial fistulae, omphalocele, diaphragmatic hernias, and uterus didelphis. We also point to the clinical overlap of *SPECC1L* syndrome with mild Baraitser-Winter craniofrontofacial syndrome: they share similar dysmorphic features (wide, short nose with a large tip, cleft lip and palate, blepharoptosis, retrognathia, and craniosynostosis), although intellectual disability, neuronal migration defect, and muscular problems remain largely specific to Baraitser-Winter syndrome. In conclusion, we suggest that patients with pathogenic variants in *SPECC1L* should not be described as “dominant (or type 2) Opitz GBBB syndrome”, , and instead should be referred to as “*SPECC1L* syndrome” as both disorders show distinctive, non overlapping developmental anomalies beyond facial communalities.

## Keywords

Opitz BBBG syndrome, Teebi hypertelorism syndrome, *SPECC1L*, *MID1*, nosology, omphalocele, bicornuate uterus

## Introduction

John Opitz reported as distinct X-linked disorders the G syndrome (Opitz et al., 1969a) and the BBB syndrome (Opitz et al., 1969b) that shared hypertelorism and hypospadias. G syndrome was mainly distinguished by the presence of laryngeal malformations. Both disorders were tentatively merged on clinical grounds (Verloes et al., 1989) and finally shown to be the same disorder when pathogenic variants in *MID1*, an X-linked gene which encodes a microtubule-associated cytoskeletal protein, were identified with both phenotypes without genotype-phenotype correlation (Quaderi et al., 1997). Recently, a variant in *MID2* (also X-linked) was also incriminated in a single family with mild GBBB (Geetha et al., 2014; Li et al., 2016). The distinctive facial features of the X-linked Opitz syndrome (Opitz GBBB syndrome, type I; OMIM 300000) are hypertelorism, prominent forehead, broad nasal bridge and anteverted nares. Congenital anomalies include hypospadias, cleft lip/palate, laryngeal and tracheoesophageal abnormalities (typically: cleft larynx), imperforate anus and cardiac defects. Developmental delay and intellectual disability are inconstant. Some individuals thought to have Opitz syndrome on clinical grounds were shown to carry a 22q11 deletion (Fryburg et al., 1996).

An autosomal locus was mapped on 22q11 (Robin et al., 1995), based on a large “unusual G syndrome” pedigree reported in 1988 (Allanson, 1988) (Opitz GBBB syndrome, type II: OMIM 145410). In 2014, a variant in *SPECC1L* was identified in Allanson’s family, still considered by the authors as Opitz syndrome (Kruszka et al., 2015), and in a second family. Both were identified among a series of 21 pedigrees selected for the presence of a craniofacial dysmorphic syndrome reminiscent of Opitz syndrome. In Kruszka’s family 1 (Kruszka et al., 2015), affected individuals spanned three generations. The proband presented with congenital diaphragmatic hernia, vesicoureteral reflux and deafness. His brother had metopic craniosynostosis, aortic stenosis and tracheomalacia. Their mother had bilateral cleft lip and palate, congenital umbilical hernia and bicornuate uterus. The three affected family members had similar facial features, including hypertelorism with slightly downslanting palpebral fissures, prominent forehead, a prominent nasal root, and a large nose with a large tip (with a median groove in the second boy), arched eyebrows and retrognathia. In Kruszka’s second family, previously described by Judith Allanson (Allanson, 1988) and reported as Family 1 in the article establishing the linkage of the autosomal dominant form of Opitz to chromosome 22q11.2 (Robin et al., 1995), the proband girl had sagittal craniosynostosis, cleft palate, swallowing difficulties and

stridor, bilateral hearing loss, ventricular dilation, ureteral reflux, and umbilical hernia. Her dysmorphism included wide forehead with prominent metopic suture, widow's peak, a marked hypertelorism, downslanting palpebral fissures, prominent nasal root and bridge, a midline groove in the tip of the nose, a wide and poorly defined philtrum, and posteriorly rotated ears. Her sister had hypertelorism and high, broad nasal bridge. Her father and his four siblings had large head circumferences, hypertelorism, down-slanting palpebral fissure, high and broad nasal bridge, wide nasal base with a hooked tip, and long columella. The father had a non-specified upper gastrointestinal malformation. One paternal uncle had a unilateral cleft lip and palate. None of the males had hypospadias.

Ahmad Teebi described in 1987 a four-generational Arabian family (Hypertelorism, Teebi type: OMIM 145420) in which 16 individuals showed a striking dysmorphism, with male-to-male transmission (Teebi, 1987). Clinical details were provided for six of them. Their phenotype included severe hypertelorism, widow's peak, mildly downslanting palpebral fissures, proptosis, ptosis, broad nasal bridge, short nose with a large tip in some, long deep philtrum and a thin upper lip. They had mild interdigital webbing and shawl scrotum, but none of the males had hypospadias. Umbilical hernia was present in two out of six patients. Intelligence and stature were normal in all of them. Thirteen other patients were subsequently reported with a purported clinical diagnosis of Teebi syndrome (reviewed in (Han et al., 2006)) A duplication of 937 kb in the X chromosome encompassing *EFNB1* and two flanking genes (*PJA1* and *STARD8*) was recently shown to segregate with marked hypertelorism and mild nail ridging, but no craniosynostosis, in three female patients from three generations. The authors described this family as X-linked Teebi hypertelorism syndrome (Babbs et al., 2011). We recently reported heterozygous variants in *SPECC1L* in two families clinically diagnosed with Teebi hypertelorism syndrome (Bhoj et al., 2015).

Cerebrofrontofacial syndromes were tentatively delineated by Robin Winter (Winter, 2001) for patients with frontonasal anomalies (broad nose, flared nares, hypertelorism, epicanthus), dysplastic ears and often CNS anomalies. Many of them, retrospectively, fitted a diagnosis of Baraitser-Winter cerebrofrontofacial syndrome (BWCF). BWCF is caused by pathogenic variants in *ACTB* (Baraitser-Winter syndrome 1: OMIM 243310) or *ACTG1* (Baraitser-Winter syndrome 2: OMIM 614583) (Riviere et al., 2012). Individuals with causative variants in either gene show a broad and rather variable phenotype, with marked hypertelorism, sometimes ridged metopic suture, ptosis, arched eyebrows, wide, short and upturned nose and a constellation of malformations comprising cleft lip and

palate, ocular coloboma, predominantly frontal pachygyria, muscle waste at shoulder girdle, sensorineural deafness, and usually intellectual deficiency (Verloes et al., 2015).

*SPECC1L* (Sperm antigen with calponin homology and Coiled-Coil domains 1 Like) is located in 22q11.23 (genomic coordinates GRCh38:22:24,270,816-24,417,739). The protein coded by *SPECC1L* shows several functional domains: a calponin-like actin-binding, a 2-oxo-acid dehydrogenase, an acyltransferase component, and a lipoyl-binding domain. *SPECC1L* protein is expressed broadly in many tissues, but its expression is prominent in neural crest cell populations of the developing facial primordia. *In situ* hybridization of mouse *Specc1l* showed prominent expression in the maxillary prominence and lateral nasal processes, the eyes and limbs at embryonic day E9.5-E10.5 (Saadi et al., 2011). Homozygous LOF mutants are embryonic lethal and show impaired neural tube closure and defective cranial neural crest cells delamination (Wilson et al., 2016). *SPECC1L* is a cytoskeletal protein that associates with both actin and microtubules to affect larger cytoskeletal function. It colocalizes with acetylated  $\alpha$ -tubulin and F-actin, and is observed in a ring around  $\gamma$ -tubulin containing centrioles, possibly in the microtubule organizing center. Actin cytoskeleton reorganization is required for adequate cell adhesion and migration. *SPECC1L* may play a role in cytoskeleton organization and acetylated  $\alpha$ -tubulin microtubule stabilization. Overexpression or reduction of *SPECC1L* results in actin reorganization defects. Endogenous *SPECC1L* colocalizes with filamentous actin and acetylated  $\alpha$ -tubulin of the mitotic spindle, suggesting a role for *SPECC1L* in cytokinesis and spindle organization. *SPECC1L* is required for proper cell adhesion and migration: in vitro, *SPECC1L* deficiency causes altered adhesion of cultured cells to the growth substrate (Saadi et al., 2011). In a mouse model, loss of *Specc1l* increases the staining of adherens junctions in the neural folds, whereas their dissolution is expected to allow neural crest cell delamination. This function appears to be mediated through PI3K-AKT signaling (Wilson et al., 2016). Thus, *SPECC1L* may mediate transduction of signals required to remodel the actin cytoskeleton during cell adhesion and migration and is a regulator of adherens junction stability. Dysfunction of *SPECC1L* disrupts the cell adhesion-based signaling necessary for correct neural crest cell behavior during craniofacial morphogenesis, including the expression of *CHD1* and *CTTNB1*. *MID1* is expressed in a subset of cranial neural crest cells that migrate to populate the branchial arches and frontonasal process. *MID1* is an RBCC (RING-finger, B-boxes and Coiled-coil) scaffold protein. It forms a large microtubule-associated protein complex that stabilizes microtubules. It also forms a translational activator complex.

Finally, it plays a role as ubiquitin E3 ligase degrading the microtubule protein phosphatase 2A and thus activating mTOR pathway. Variants in *MID1*, *SPECC1L* and ubiquitous actins express overlapping phenotypes that may indicate convergent functions, but the real interactions between those proteins in neural crest biology remain to be described (Latta and Golding, 2012; Winter et al., 2016).

In this paper, we report 16 patients from eight unreported families with *SPECC1L* pathogenic variants and a further individual of a previously published family and revisit the nosology of GBBB and Teebi syndromes.

## Methods

All patients were gathered through a clinical multicentric collaboration. Authors obtained written consents of the patient or their parents (for patients < 16 years). Patients were ascertained both through targeted Sanger testing of *SPECC1L* based on suggestive phenotypic features or through exome sequencing (see table 1 for details). Exome capture was carried out using Agilent SureSelect Human All Exon kit (Agilent Technologies, Santa Clara, CA, USA), guided by the manufacturer's protocols. Parental samples, where available, were also tested. Variant annotation was performed using ACMG variant classification rules (Richards et al., 2015). Variants were declared to ClinVar.

## Results

### Family 1 (Figure 1)

**Individual 1-III-1.** This individual is the first child of non-consanguineous parents, born at 36 weeks of gestation (WG). He had bilateral cleft lip and palate, left diaphragmatic hernia that was operated at the first day of life, bilateral inguinal hernia (operated in infancy) and normal genitalia. He sat at eighteen months and was able to walk at age 3. He was first seen in the genetic clinics at age 4 (Fig 2a,b), where a tentative diagnosis of Teebi hypertelorism syndrome was suggested. He had a triangular face, mild hypertelorism with intercanthal distance (ICD) of 35 mm, long, slightly downslanted palpebral fissures and mild ptosis, prominent orbital ridges with arched eyebrows, prominent nasal root, a short and large nose, with a large, bulbous tip, flared alae nasi, tick columella, a long philtrum with surgical scars, and a receding chin. Fingers and feet were relatively short. Head circumference was 51 cm (+0.18 SD). At that time, skeletal survey excluded craniosynostosis. MRI disclosed short corpus callosum. EEG showed an irritative wave pattern on the occipital area, but he never had seizures. Heart and kidneys ultrasound scans were normal. His development was severely delayed: He has severe intellectual disability, no speech and

major behavioral problems in relation with an autism spectrum disorder (ASD), treated by risperidone and cyamemazine. At his last assessment, at age 19 (Fig 2c,d), he was still non-verbal, eating pureed foods and was not toilet trained at night.

**Individual 1-II-1.** This woman (Fig 2 e-g), the mother of 1-III-1, was born at term to non-consanguineous parents. She followed normal schooling, with support. She had a triangular face, mild hypertelorism (ICD 35 mm) with long, slightly downslanted palpebral fissures and mild ptosis, prominent orbital ridges with arched eyebrows, prominent, flat nasal root, short and large nose, with a large bulbous tip, small alae nasi, thick columella, a long philtrum with smooth grooves, a large mouth, low set ears with long earlobes and preauricular pits and a receding chin. Umbilical hernia was operated at age 4. She had bicornuate uterus and normal kidneys.

**Individual 1-II-2.** This man was individual 1-II-1's brother. He was born at 33 WG. He underwent surgery for inguinal and umbilical hernias and had hyperopia (+3 d). He had a normal development and followed normal schooling, albeit with difficulties. In early adulthood, a single, painful tumor of the right common fibular nerve was diagnosed. His right leg was amyotrophic compared to the left. After extensive neuroimaging (including brain and medullar MRI) that excluded NF1, a diagnosis of solitary schwannoma or neurofibroma was proposed. He had a triangular face, major hypertelorism (ICD 45 mm) with long palpebral fissures and mild ptosis, prominent orbital ridges with thick, arched eyebrows, prominent nasal root with short and large nose, with a large, flat tip, small alae nasi, thick columella, a long, smooth philtrum with a thin vermillion border, and a receding chin (Fig 2 j,k). The ears were small, triangular shaped, with preauricular pits and tags.

**Individual 1-I-1.** This woman, the mother of individuals 1-II-1 and 1-II-2, was born prematurely with a reported birth weight of 750 g. She had midline cleft palate (surgically repaired during infancy). She developed a secondary hydrocephalus. She had bicornuate uterus and normal kidneys. She underwent surgery for intestinal obstruction of imprecise etiology at age 46 years. In her fifties, she developed non-insulin-resistant diabetes mellitus (despite absence of obesity) and glaucoma. She was illiterate but nevertheless had a normal, independent social life. She had marked hypertelorism (ICD 40 mm) with long, slightly downslanted palpebral fissures and mild ptosis, prominent orbital ridges, arched eyebrows, prominent, flat nasal root with marked lateral edges, a short and large nose, with a bulbous tip, small alae nasi, thick columella, a long philtrum with smooth grooves, thin vermillion border, a large

mouth, low set ears with long earlobe and preauricular pits, and a receding chin (Fig 2 h,i). She had unilateral, probably congenital deafness.

All affected family members were found to carry the *SPECC1L* c.3293G>A p.(Arg1098Gln) variant (Table 1).

## Family 2

**Individual 2-1.** This man was born at term to healthy parents. He had a 4 cm omphalocele containing gut, surgically repaired. Large anterior fontanel and hypertelorism were also noted. He underwent surgery for cryptorchidism and obstruction of the ureteropelvic junction at 3 months and 12 years of age respectively. He had normal intelligence and normal academic achievement. His dysmorphism (Fig 2 l) included hypertelorism (ICD: 5 cm), downslanting palpebral fissures, wide nasal bridge, prominent supraorbital ridges, and pterygium colli (Fig 2 o). In addition, he had a mild left hemihypertrophy (circumferences of 37cm vs 34 cm for left and right calves respectively), already reported in infancy. A *SPECC1L* c.1258G>A p.(Glu420Lys) variant was found to be *de novo* in him (Table 1).

## Family 3

**Individual 3-1.** This boy was born to healthy non-consanguineous parents. He was referred to genetic clinics at the age of 4 months. He had hypertelorism, and a broad prominent nasal root and bridge (Fig 2 o-q), swallowing difficulties. Initial psychomotor development was normal. Follow up in the third year showed mild language delay. A *de novo* *SPECC1L* c.1382G>A p.(Arg461Gln) variant was identified in him (Table 1).

## Family 4

**Individual 4-I-1.** This female individual was born by cesarean section at term to healthy, unrelated parents after an uneventful pregnancy. At birth, she was noted to have prominent ocular hypertelorism, a natal tooth, atrial septum defect and umbilical hernia. She had normal development. She was first seen in genetics after the termination of pregnancy for Patient 4-2. At that time (Fig 2 m, n), she was noted to have short stature, short limbs, short fingers and toes, arched eyebrows, high and broad nasal bridge, anteverted nares, long philtrum, micrognathia (surgically repaired), and bicornuate uterus. Before thorough syndromic assessment and molecular diagnostics established the diagnosis, the patient became pregnant again. Ultrasound examination and subsequent fetal autopsy revealed a phenotype similar to that of the first fetus.

**Individual 4-II-1.** The routine ultrasound scan at 20 WG showed that this female fetus of Individual 4-1 had a severe diaphragmatic hernia. Pregnancy was terminated at 22 WG. Birth length, weight and HC were in the normal range.

Necropsy revealed ocular hypertelorism, high and broad nasal bridge, anteverted nares, long philtrum, large left-sided posterior diaphragmatic hernia with the spleen, pancreas, ventricle and left liver lobe in the thoracic cavity (leading to pulmonary hypoplasia), very large ovaries and a bicornuate uterus.

**Individual 4-II-2.** Ultrasound scan at 15+6 WG showed that this second female fetus of Individual 4-1 had a severe diaphragmatic hernia and abnormal brain imaging: inward scalloping of the frontal bones (“lemon sign”), and a “banana shaped” cerebellum (due to a shallow posterior fossa). Pregnancy was terminated at 17+3 WG. Birth length, weigh and HC were in the normal range. Autopsy revealed prominent forehead, low set and posteriorly rotated ears, ocular hypertelorism, high and broad nasal bridge, anteverted nares, median groove of the tip of the nose, long philtrum, wide mouth, micrognathia, muscular ventricular septum defect of the heart, complete absence of the left side of the diaphragm with spleen, pancreas, ventricle, and left liver lobe in the thoracic cavity (leading to pulmonary hypoplasia), enlarged ovaries and bicornuate uterus. No dysraphism was observed despite the abnormal head imaging.

A c.1258G>A p.(Glu420Lys) variant in *SPECC1L* was found to be *de novo* in 4-1 and inherited in the two fetuses (Table 1).

## Family 5

**Individual 5-1.** The proband of family 5 was clinically diagnosed with Teebi hypertelorism syndrome after referral to ophthalmogenetics at age 23 years (Fig 2 r). She has no major medical issues other than her dysmorphic facial features. These include ocular hypertelorism, prominent forehead, arched eyebrows, bilateral ptosis (L>R), a broad nasal bridge, anteverted nares, long philtrum, and mild micrognathia.

**Individual 5-2.** The full sister of individual 5-1 (Fig 2 s) was found to have similar facial features with no additional medical issues. At age 25 years, her facial features included ocular hypertelorism, prominent forehead, a broad nasal bridge, and a long philtrum.

A *SPECC1L* variant, c.1258G>A p.(Glu420Lys) was found in both affected sisters (Table 1). The parents of both sibs were not available for testing.

## Family 6

**Individual 6-II-1.** This individual is the second child of consanguineous parents (coefficient of relationship 1/8). He was born at 40 weeks of gestation, with normal birth parameters. He had cryptorchidism, umbilical and unilateral

inguinal hernia that were operated at 21 months. The growth and weight gain were normal until five months when he started failure to thrive. At 12 months, steroid-resistant nephrotic syndrome was diagnosed. By the age of 3 years 10 months, he developed stage 5 chronic kidney disease, and peritoneal dialysis was started. The renal biopsy revealed minimal change disease. Renal failure caused arterial hypertension, anemia, secondary hyperparathyroidism, and growth delay with short stature. He also has mild developmental delay. Craniofacial anomalies included large forehead, thick eyebrows, hypertelorism, downslanted palpebral fissures, upturned nostrils with a wide tip and short columella, wide mouth with a tented upper lip and a marked cupid's bow, and large ears. Brain MRI and cardiac evaluation were normal. Before WES, an analysis of a nephrotic syndrome NGS gene panel analysis was performed: no clinically relevant variant was found in *ACTN4*, *ADCK4*, *ARHGDI1*, *DGKE*, *EMP2*, *LAMB2*, *NPHS1*, *NPHS2*, *PLCE1*, *PTPRO*, *WT1*. His renal disorder was felt to be unrelated to *SPECC1L*.

**Individual 6-II-2.** This nine-year-old girl is the sister of individual 6-II-1. She was referred to the genetics clinics at age three years, for etiological investigation of developmental delay, poor growth and congenital heart defect (atrial septal defect and subaortic ventricular septal defect). Karyotype, MLPA for 22q11 and 10p14 regions, and metabolic tests (plasma amino acids, urine organic acids and carbohydrate-deficient transferrin) were normal. At nine-years-old she has learning difficulties. Her growth parameters (length and weight) were at -2SD. She has no renal problems. She had a triangular face with thick eyebrows, hypertelorism, downslanted palpebral fissures, upturned tip of the nose, wide mouth with everted lower lip.

**Individual 6-I-1.** This 35-year-old man is the father of individuals 6-II-1 and 6-II-2. He has a history of learning difficulties. He has neither renal problems nor cardiac anomalies. He had a widow's peak, thick eyebrows, bulbous tip of the nose, a long philtrum, and thick lips. His palpebral fissures were normal.

All three affected family members carry the *SPECC1L* c.3026A>C p.(Tyr1009Ser) variant (Table 1).

## Family 7

**Individual 7-1.** This individual is a two-month-old female born to a 38-year-old mother and 45-year-old father at 40 weeks of gestation. Prenatally there were concerns for a small ventral septal defect, two vessel umbilical cord, pelviectasis, and large placenta, but karyotype and SNP microarray from amniocytes were normal. She weighed 3385 g (50<sup>th</sup> centile) and was 53cm long (95<sup>th</sup> centile), and her head circumference was 34cm (50<sup>th</sup> centile). There were no

complications with the delivery and her APGAR scores were 9 and 9. Abnormal facial features prompted a genetics consult, which noted a prominent widow's peak, hypertelorism with a interpupillary distance of 5.25 cm (>97<sup>th</sup>%, 50<sup>th</sup>% for 9 years), a short nasal bridge, a thin upper lip, but no other congenital anomalies. On further post-natal imaging, she was noted to have uterus didelphys, but no other urogenital abnormalities. Brain ultrasound was normal except for possible thinning of the corpus callosum. A post-natal echocardiogram was normal with no evidence of a ventral septal defect. She has normal tone and development. There is no family history of hypertelorism or congenital anomalies. She was found to carry a *de novo* c.1246G>A p.(Ala416Thr) variant in *SPECC1L* (Table 1).

### Family 8

**Individual 8-1.** This individual is the maternal cousin of Kruzka's Family A (Kruzka et al., 2015). She is currently 32-years-old and has developed multiple medical conditions. She was born with hypertelorism, ear pits, an umbilical hernia, bicornuate uterus, simple sacral dimple, and a thyroglossal duct cyst. She had normal growth and development and was able to graduate from secondary school. While in her second decade of life she developed pulmonary hypertension, diastolic heart failure, microvascular disease, and vasospastic angina. She has a hiatal hernia with gastroparesis and gastroesophageal reflux disease. She has astigmatism, amblyopia, and dry corneas. There has also been a concern for a mitochondrial myopathy based on her cardiac condition and skeletal muscle weakness. She was found to carry the same familial *SPECC1L* c.1189A>C p.(Thr397Pro) variant (Table 1).

### Family 9

**Individual 9-1.** This individual is a 12 months old male born to a 29-year-old mother and 41-year-old father at 38 weeks of gestation by cesarean section. Pregnancy was complicated by polyhydramnios. At birth, he presented with congenital diaphragmatic hernia and dysmorphic features including frontal bossing and wide fontanel. At 4-month physical exam showed prominent forehead, large fontanelle, wide open metopic suture, wide set eyes, wide nasal bridge, small bilateral ear pits in the medial end of upper helix, long and deep philtrum, pectus excavatum, umbilical hernia, bilateral undescended testicles, and brachyclinodactyly of 5<sup>th</sup> fingers (Fig 2 t). He was intubated after birth and placed on ECMO. The diaphragmatic hernia was repaired on day of life 3 and ECMO decannulation was done on day of life 5. He remained in the NICU for two months due to poor feeding and some residual oral aversion, and was eventually discharged home with a G-tube. His hearing and echocardiogram were normal. He wears glasses for

significant hyperopia. FISH for 12p tetrasomy to rule out Pallister Killian syndrome and whole-genome microarray analysis were non-diagnostic. He was found to carry a *SPECC1L* c.3293G>A p.(Arg1098Gln)variant (Table 1).

## Discussion

### *SPECC1L* associated syndromes

Heterozygous loss of function of *SPECC1L* causes Tessier IV oblique facial cleft (ObFC) : disruption of intron 14 of *SPECC1L* by a de novo t(1;22)(q21.3;q11.23) translocation leading to *SPECC1L* haploinsufficiency was observed in a girl with Tessier IV ObFC, cleft palate, microphthalmia, palpebral coloboma and talipes deformity; a *de novo* functionally defective variant (NM\_015330.2 (*SPECC1L*\_v001) c.1244A>C (p.Gln415Pro) ) was identified by the same group in an individual with isolated Tessier IV ObFC and normal eyes (facial clefting, oblique, type 1 - OMIM 600251). (Dasouki et al., 1988; Saadi et al., 2011).

More recently, missense variants (c.1189A>C - p.(Thr397Pro) - and c.3247G>A - p.(Gly1083Ser)) were reported in two large pedigrees considered as Opitz GBBB syndrome (Kruszka et al., 2015), one of them previously described by Judith Allanson (Allanson, 1988) (a diagnosis that we question below). We also reported heterozygous missense variants in *SPECC1L* (Bhoj et al., 2015) in a patient and his affected mother, previously-proposed as a new syndrome resembling Teebi hypertelorism and Aarskog syndromes (Hoffman et al., 2007), and in a single patient with typical Teebi phenotype.

A total of 31 patients (14 males and 17 females) from 12 families are recorded with *SPECC1L* missense variants (including 2 recurrent mutations) and a clinical diagnosis of GBBB or Teebi syndrome. The phenotype that emerges from this series is summarized in Table 2 and supplementary Table 1. None of them has Tessier IV cleft, suggesting that the syndrome discussed here occurs by another mechanism than haploinsufficiency.

*SPECC1L*-related syndrome clearly belongs to a common spectrum of developmental anomalies with shared dysfunction of several proteins involved in microtubule biology, particularly in neural crest cells. Despite their overlap, each of these genes has some phenotypic specificity that are underlined in Table 3: *SPECC1L* appears to play a specific role in branchial morphogenesis, diaphragmatic development, umbilical ring closure and fusion of the Mullerian ducts, which are seldom affected in the other syndromes.

## Comparing *SPECC1L*- and *MID1*-related disorders

Inheritance of Opitz syndrome has been subject of a long debate: more severe expression in males was initially suggesting X-linked inheritance. Multiple reports of male-to-male inheritance lead subsequently to the conclusion that GBBB syndrome was autosomal dominant. In 1995, Robin showed that at least one autosomal and one X-linked forms of Opitz could be distinguished (Robin et al., 1995). Retrospective review of the other older reports showing male-to-male is disappointing: a convincing phenotype was reported in a father and son with hypertelorism, and hypospadias ; the son further had severe manifestations, including stridor, hoarse voice and feeding difficulties (Farndon and Donnai, 1983). But the diagnosis of GBBB appears uncertain or too poorly documented in other reports (Chemke et al., 1984; Funderburk and Stewart, 1978; Tolmie et al., 1987; Wilson and Oliver, 1988).

Robin's segregation analysis was performed in nine pedigrees, and showed linkage to DXS987 on X chromosome in three multigenerational pedigrees and to D22S345 in 22q in six further multigenerational pedigrees (four of them with male-to-male transmission of the phenotype). They compared the two forms (Robin et al., 1996) and stated that anorectal malformations, posterior laryngeal cleft and anteverted nares were not seen in 22q-linked families, and that the craniofacial appearance was different, with broader forehead and coarser traits in the 22q group. In 22q-linked families, 25% of the carriers had ID. "Structural laryngotracheal anomalies" (but not cleft larynx) were mentioned in 2/13 males and 1/7 females within the 22q-linked pedigrees. Compared to our data, the main discordance was the presence of hypospadias in 5/16 males of 22q-linked families. Retrospectively, using present criteria, the diagnosis of GBBB syndrome may not be perfectly convincing in some of these families. For instance, the Gestalt of X-linked family 2 (with male-to-male transmission of hypertelorism, and hypospadias in a son (Robin et al., 1996)) appears surprisingly mild to fit a diagnosis of Teebi or GBBB. Hence, the contradiction between our observation and Robin's series may reflect the use of looser clinical criteria than what would be accepted now to consider Opitz or *SPECC1L*-related syndrome. Because of these uncertainties in the clinical diagnosis, we decided to limit the comparison to the patients with proven causative variants. In Table 2, we tabulated the most striking features of 31 individuals with *SPECC1L* syndrome and compared them to the phenotypic profile of males with *MID1* syndrome and to the full cohort of *MID1* individuals. For *MID1*, we used the tables published by Li (Li et al., 2016)

who updated two previous reviews (Ferrentino et al., 2007; Fontanella et al., 2008) encompassing a total of 184 GBBB patients.

### Older clinical reports of autosomal dominant Teebi and Opitz syndromes

We reviewed nine reports published between 1987 and 2006 as Teebi syndrome, for which no molecular nor cytogenetic investigations are available. They total 19 individuals, including the six well-described patients from Teebi's article. Among those patients, in our opinion, four reports beside the original one (Teebi, 1987) fit the clinical spectrum of *SPECC1L* (Stratton, 1991; Koenig, 2003; Toriello and Delp, 1994; Han et al., 2006). Male to male transmission was observed in Teebi's and Stratton's report. Umbilical hernia and preauricular pits were reported repeatedly. Two other reports are more likely dealing with BWCF (Tsai et al., 2002; Machado-Paula and Guion-Almeida, 2003). Three have unclassifiable syndromes with hypertelorism (Nakagawa et al., 1998; Tsukahara et al., 1995).

### Overlap with Baraitser-Winter cerebrofrontofacial syndrome

The facial dysmorphism of BWCF (hypertelorism, broad nose with large tip, ptosis, and highly arched eyebrows, and ridged metopic suture) share similarities with both Opitz and Teebi syndrome. Indeed, some of the individuals in our paper were originally thought to have BWCF syndrome. Table 3 points out the dissimilarities between the three syndromes.

### Conclusion

Despite the resemblances between *MID1*-, *SPECC1L*- and actin-linked syndromes (which are explained by the pathophysiological commonalities in cell biology), it is important for living nosology to continue to analyze separately phenotypes of genotyped cohorts, in order to build gene-specific natural histories and to allow more accurate genetic counseling. The use of *type 1* to *type n* is usually justified in syndromology when the phenotypes caused by variation in different genes are not distinguishable, such as in Bardet-Biedl syndrome. Beyond facial similarities, the general pattern of developmental anomalies caused by *SPECC1L* (with defects of the abdominal walls and diaphragm, uterine and branchial defects, sometimes craniosynostosis and aortic root dilation) is different enough from the pattern associated with *MID1* (with urogenital malformations in males and laryngeal cleft) to justify to discard "Opitz GBBB type 2" from the nosology and to replace it by *SPECC1L*-related syndrome – or Teebi syndrome.

A clear distinction between *SPECC1L*-related syndrome and *MID1*-related syndrome is also important for the genetic counseling of affected patients, as the medical or surgical complications are not superimposable.

At the time when exome sequencing enters clinical practice, reanalyzing published data keeping in mind the historical perspective, the history and evolution of syndrome delineation and the possible approximations made by our mentors in a time where syndrome recognition was a matter of art, without biological substrate, remains an important task for dysmorphologists in the era of genomic medicine.

## Disclosure

the authors have no conflict of interest to disclose

## Supplementary material

### Supplementary Table 1

Tabulated individual record of the 31 patients with *SPECC1L* variants (xls file)

## Bibliography

- Allanson, J.E., 1988. G syndrome: an unusual family. *Am. J. Med. Genet.* 31, 637–642.
- Babbs, C., Stewart, H.S., Williams, L.J., Connell, L., Goriely, A., Twigg, S.R.F., Smith, K., Lester, T., Wilkie, A.O.M., 2011. Duplication of the *EFNB1* gene in familial hypertelorism: imbalance in ephrin-B1 expression and abnormal phenotypes in humans and mice. *Hum. Mutat.* 32, 930–938. <https://doi.org/10.1002/humu.21521>
- Bhoj, E.J., Li, D., Harr, M.H., Tian, L., Wang, T., Zhao, Y., Qiu, H., Kim, C., Hoffman, J.D., Hakonarson, H., Zackai, E.H., 2015. Expanding the *SPECC1L* mutation phenotypic spectrum to include Teebi hypertelorism syndrome. *Am. J. Med. Genet. A.* 167A, 2497–2502. <https://doi.org/10.1002/ajmg.a.37217>
- Chemke, J., Shor, E., Ankori-Cohen, H., Kazuni, E., 1984. Male to male transmission of the G syndrome. *Clin. Genet.* 26, 164.
- Dasouki, M., Barr, M., Erickson, R.P., Cox, B., 1988. Translocation (1;22) in a child with bilateral oblique facial clefts. *J. Med. Genet.* 25, 427–429.
- Farndon, P.A., Donnai, D., 1983. Male to male transmission of the G syndrome. *Clin. Genet.* 24, 446–448.
- Ferrentino, R., Bassi, M.T., Chitayat, D., Tabolacci, E., Meroni, G., 2007. *MID1* mutation screening in a large cohort of Opitz G/BBB syndrome patients: twenty-nine novel mutations identified. *Hum. Mutat.* 28, 206–207. <https://doi.org/10.1002/humu.9480>
- Fontanella, B., Russolillo, G., Meroni, G., 2008. *MID1* mutations in patients with X-linked Opitz G/BBB syndrome. *Hum. Mutat.* 29, 584–594. <https://doi.org/10.1002/humu.20706>
- Fryburg, J.S., Lin, K.Y., Golden, W.L., 1996. Chromosome 22q11.2 deletion in a boy with Opitz (G/BBB) syndrome. *Am. J. Med. Genet.* 62, 274–275. [https://doi.org/10.1002/\(SICI\)1096-8628\(19960329\)62:3<274::AID-AJMG13>3.0.CO;2-H](https://doi.org/10.1002/(SICI)1096-8628(19960329)62:3<274::AID-AJMG13>3.0.CO;2-H)
- Funderburk, S.J., Stewart, R., 1978. The G and BBB syndromes: case presentations, genetics, and nosology. *Am. J. Med. Genet.* 2, 131–144.

- Geetha, T.S., Michealraj, K.A., Kabra, M., Kaur, G., Juyal, R.C., Thelma, B.K., 2014. Targeted deep resequencing identifies MID2 mutation for X-linked intellectual disability with varied disease severity in a large kindred from India. *Hum. Mutat.* 35, 41–44. <https://doi.org/10.1002/humu.22453>
- Han, X.-D., Cox, V., Slavotinek, A., 2006. Atrioventricular block and wiry hair in Teebi hypertelorism syndrome. *Am. J. Med. Genet. A.* 140, 1960–1964. <https://doi.org/10.1002/ajmg.a.31439>
- Hoffman, J.D., Irons, M., Schwartz, C.E., Medne, L., Zackai, E.H., 2007. A newly recognized craniosynostosis syndrome with features of Aarskog-Scott and Teebi syndromes. *Am. J. Med. Genet. A.* 143A, 1282–1286. <https://doi.org/10.1002/ajmg.a.31780>
- Koenig, R., 2003. Teebi hypertelorism syndrome. *Clin. Dysmorphol.* 12, 187–189. <https://doi.org/10.1097/01.mcd.0000077563.66911.c4>
- Kruszka, P., Li, D., Harr, M.H., Wilson, N.R., Swarr, D., McCormick, E.M., Chiavacci, R.M., Li, M., Martinez, A.F., Hart, R.A., McDonald-McGinn, D.M., Deardorff, M.A., Falk, M.J., Allanson, J.E., Hudson, C., Johnson, J.P., Saadi, I., Hakonarson, H., Muenke, M., Zackai, E.H., 2015. Mutations in SPECC1L, encoding sperm antigen with calponin homology and coiled-coil domains 1-like, are found in some cases of autosomal dominant Opitz G/BBB syndrome. *J. Med. Genet.* 52, 104–110. <https://doi.org/10.1136/jmedgenet-2014-102677>
- Latta, E.J., Golding, J.P., 2012. Regulation of PP2A activity by Mid1 controls cranial neural crest speed and gangliogenesis. *Mech. Dev.* 128, 560–576. <https://doi.org/10.1016/j.mod.2012.01.002>
- Li, B., Zhou, T., Zou, Y., 2016. Mid1/Mid2 expression in craniofacial development and a literature review of X-linked opitz syndrome. *Mol. Genet. Genomic Med.* 4, 95–105. <https://doi.org/10.1002/mgg3.183>
- Machado-Paula, L.A., Guion-Almeida, M.L., 2003. Teebi hypertelorism syndrome: additional cases. *Am. J. Med. Genet.* 117A, 181–183.
- Nakagawa, M., Kondo, M., Matsui, A., 1998. Teebi hypertelorism syndrome with tetralogy of Fallot. *Am. J. Med. Genet.* 77, 345–347.
- Opitz, J.M., Frias, J.L., Gutenberg, J.E., Pellett, J.R., 1969a. The G syndrome of multiple congenital anomalies. *Birth Defects Orig. Artic. Ser. V(2)*, 95–101.
- Opitz, J.M., Summitt, R.L., Smith, D.W., 1969b. The BBB syndrome: familial telecanthus with associated congenital anomalies. *Birth Defects Orig. Artic. Ser. V(2)*, 86–94.
- Quaderi, N.A., Schweiger, S., Gaudenz, K., Franco, B., Rugarli, E.I., Berger, W., Feldman, G.J., Volta, M., Andolfi, G., Gilgenkrantz, S., Marion, R.W., Hennekam, R.C., Opitz, J.M., Muenke, M., Ropers, H.H., Ballabio, A., 1997. Opitz G/BBB syndrome, a defect of midline development, is due to mutations in a new RING finger gene on Xp22. *Nat. Genet.* 17, 285–291. <https://doi.org/10.1038/ng1197-285>
- Richards, S., Aziz, N., Bale, S., Bick, D., Das, S., Gastier-Foster, J., Grody, W.W., Hegde, M., Lyon, E., Spector, E., Voelkerding, K., Rehman, H.L., ACMG Laboratory Quality Assurance Committee, 2015. Standards and guidelines for the interpretation of sequence variants: a joint consensus recommendation of the American College of Medical Genetics and Genomics and the Association for Molecular Pathology. *Genet. Med. Off. J. Am. Coll. Med. Genet.* 17, 405–424. <https://doi.org/10.1038/gim.2015.30>
- Riviere, J.B., van Bon, B.W., Hoischen, A., Kholmanskikh, S.S., O’Roak, B.J., Gilissen, C., Gijsen, S., Sullivan, C.T., Christian, S.L., Abdul-Rahman, O.A., Atkin, J.F., Chassaing, N., Drouin-Garraud, V., Fry, A.E., Fryns, J.P., Gripp, K.W., Kempers, M., Kleefstra, T., Mancini, G.M., Nowaczyk, M.J., van Ravenswaaij-Arts, C.M., Roscioli, T., Marble, M., Rosenfeld, J.A., Siu, V.M., de Vries, B.B., Shendure, J., Verloes, A., Veltman, J.A., Brunner, H.G., Ross, M.E., Pilz, D.T., Dobyns, W.B., 2012. De novo mutations in the actin genes ACTB and ACTG1 cause Baraitser-Winter syndrome. *Nat. Genet.* 44, 440–4, S1-2. <https://doi.org/10.1038/ng.1091>
- Robin, N.H., Feldman, G.J., Aronson, A.L., Mitchell, A.F., Weksberg, R., Leonard, C.O., Burton, B.K., Josephson, K.D., Laxova, R., Aleck, K.A., Allanson, J.E., Guion-Almeida, M.L., Martin, R.A., Leichtman, L.G., Price, R.A., Opitz, J.M., Muenke, M., 1995. Opitz syndrome is genetically heterogeneous, with one locus on Xp22 and a second locus on 22q11.2. *Nat. Genet.* 11, 459–461.
- Robin, N.H., Opitz, J.M., Muenke, M., 1996. Opitz G/BBB syndrome: clinical comparisons of families linked to Xp22 and 22q, and a review of the literature. *Am. J. Med. Genet.* 62, 305–317. [https://doi.org/10.1002/\(SICI\)1096-8628\(19960329\)62:3<305::AID-AJMG20>3.0.CO;2-N](https://doi.org/10.1002/(SICI)1096-8628(19960329)62:3<305::AID-AJMG20>3.0.CO;2-N)
- Saadi, I., Alkuraya, F.S., Gisselbrecht, S.S., Goessling, W., Cavallero, R., Turbe-Doan, A., Petrin, A.L., Harris, J., Siddiqui, U., Grix, A.W., Hove, H.D., Leboulch, P., Glover, T.W., Morton, C.C., Richieri-Costa, A., Murray, J.C.,

- Erickson, R.P., Maas, R.L., 2011. Deficiency of the cytoskeletal protein *SPECC1L* leads to oblique facial clefting. *Am. J. Hum. Genet.* 89, 44–55. <https://doi.org/10.1016/j.ajhg.2011.05.023>
- Stratton, R.F., 1991. Teebi hypertelorism syndrome. *Am. J. Med. Genet.* 39, 78–80.
- Teebi, A.S., 1987. New autosomal dominant syndrome resembling craniofrontonasal dysplasia. *Am. J. Med. Genet.* 28, 581–591. <https://doi.org/10.1002/ajmg.1320280306>
- Tolmie, J.L., Coutts, N., Drainer, I.K., 1987. Congenital anal anomalies in two families with the Opitz G syndrome. *J. Med. Genet.* 24, 688–691.
- Toriello, H.V., Delp, K., 1994. Teebi hypertelorism syndrome: report of a third family. *Clin. Dysmorphol.* 3, 335–339.
- Tsai, A.C.-H., Robertson, J.R., Teebi, A.S., 2002. Teebi hypertelorism syndrome: report of a family with previously unrecognized findings. *Am. J. Med. Genet.* 113, 302–306. <https://doi.org/10.1002/ajmg.10870>
- Tsukahara, M., Uchida, M., Shinohara, T., 1995. Teebi hypertelorism syndrome: further observations. *Am. J. Med. Genet.* 59, 59–61. <https://doi.org/10.1002/ajmg.1320590113>
- Verloes, A., Di Donato, N., Masliah-Planchon, J., Jongmans, M., Abdul-Raman, O.A., Albrecht, B., Allanson, J., Brunner, H., Bertola, D., Chassaing, N., David, A., Devriendt, K., Eftekhari, P., Drouin-Garraud, V., Faravelli, F., Faivre, L., Giuliano, F., Guion Almeida, L., Juncos, J., Kempers, M., Eker, H.K., Lacombe, D., Lin, A., Mancini, G., Melis, D., Lourenço, C.M., Siu, V.M., Morin, G., Nezarati, M., Nowaczyk, M.J.M., Ramer, J.C., Osimani, S., Philip, N., Pierpont, M.E., Procaccio, V., Roseli, Z.-S., Rossi, M., Rusu, C., Sznajer, Y., Templin, L., Uliana, V., Klaus, M., Van Bon, B., Van Ravenswaaij, C., Wainer, B., Fry, A.E., Rump, A., Hoischen, A., Drunat, S., Rivière, J.-B., Dobyns, W.B., Pilz, D.T., 2015. Baraitser-Winter cerebrofrontofacial syndrome: delineation of the spectrum in 42 cases. *Eur. J. Hum. Genet. EJHG* 23, 292–301. <https://doi.org/10.1038/ejhg.2014.95>
- Verloes, A., Le Merrer, M., Briard, M.L., 1989. BBBG syndrome or Opitz syndrome: new family. *Am. J. Med. Genet.* 34, 313–6. <https://doi.org/10.1002/ajmg.1320340303>
- Wilson, G.N., Oliver, W.J., 1988. Further delineation of the G syndrome: a manageable genetic cause of infantile dysphagia. *J. Med. Genet.* 25, 157–163.
- Wilson, N.R., Olm-Shipman, A.J., Acevedo, D.S., Palaniyandi, K., Hall, E.G., Kosa, E., Stumpff, K.M., Smith, G.J., Pitstick, L., Liao, E.C., Bjork, B.C., Czirok, A., Saadi, I., 2016. *SPECC1L* deficiency results in increased adherens junction stability and reduced cranial neural crest cell delamination. *Sci. Rep.* 6, 17735. <https://doi.org/10.1038/srep17735>
- Winter, J., Basilicata, M.F., Stemmler, M.P., Krauss, S., 2016. The MID1 protein is a central player during development and in disease. *Front. Biosci. Landmark Ed.* 21, 664–682.
- Winter, R.M., 2001. Cerebro-fronto-facial syndrome: three types? *Clin. Dysmorphol.* 10, 79–80.

## Legend of figures

### Figure 1

Pedigree of Family 1

### Figure 2

Craniofacial morphology in individuals with *SPECC1L* variants. a-d: Individual 3-1 aged 4 years and 15 years; e-g: Individual 2-1 in infancy and aged 30; h,i: individual 1-3; j,k: individual 1-4; l: individual 2-1; m,n: individual 4-1 in infancy and adult; o-q: individual 3-1 aged 4 months and 2 ½ years; r: individual 5-1; s: individual 5-2; t: individual 9-

## Legend of Tables

### Table 1

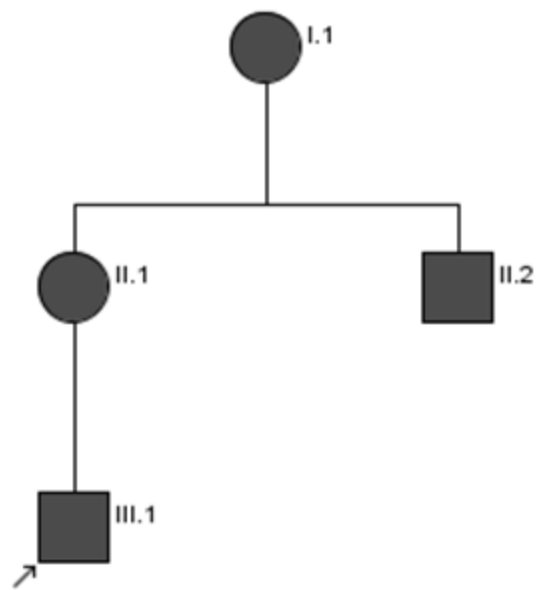
Molecular investigation of the families. *SPECC1L* variants based on RefSeq NM\_015330.4. WES: whole exome sequencing; CES: clinical exome sequencing; TSS: targeted Sanger sequencing. ACMG evidences: PS1: same amino acid change as a previously established pathogenic variant; PS2: *de novo* with parentage confirmed; PS3: well established *in vitro* or *in vivo* functional studies supportive of a damaging effect; PM2: absent from population databases; PM5: novel missense change at an amino acid residue where a different pathogenic missense change has been seen before; PP1: segregation with disease in multiple affected individuals; PP3: multiple computational evidences support deleterious effect

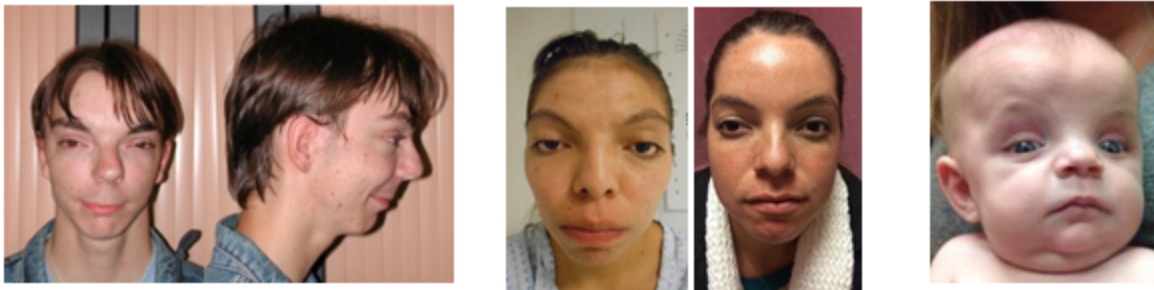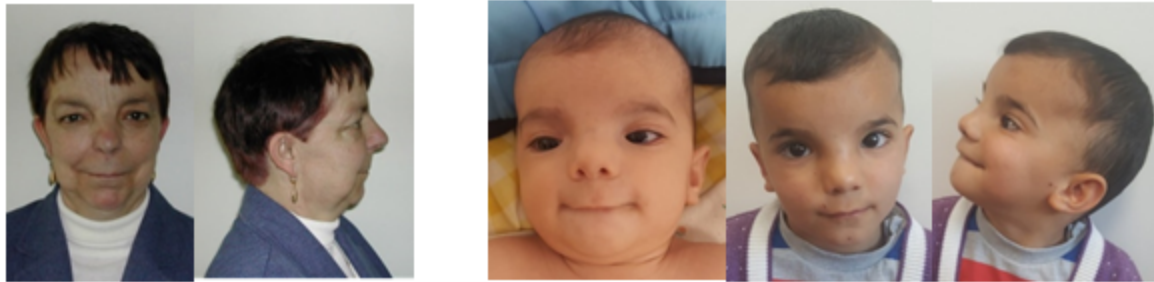
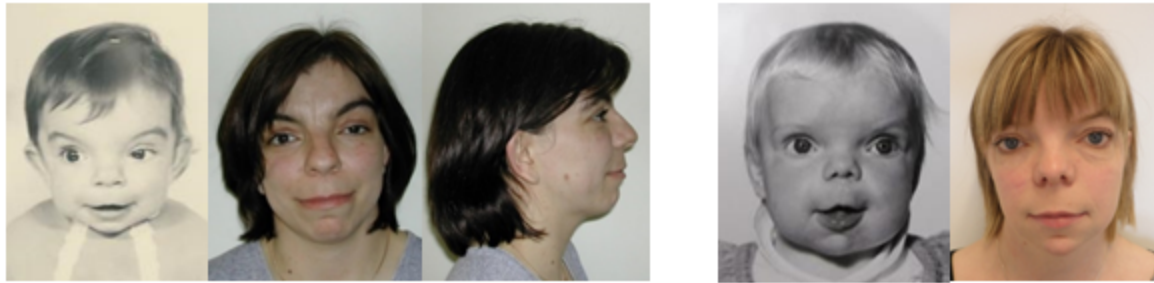
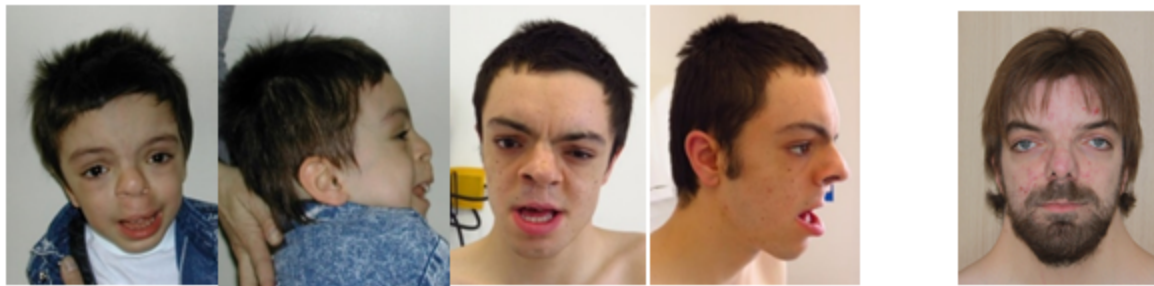
### Table 2

Clinical spectrum of 31 individuals with *SPECC1L* variants

### Table 3

Comparison of *SPECC1L* spectra with male MID1 and with Baraitser-Winter syndrome (BWS). MID1 and BWS frequencies based on the previously published compilations (Li et al., 2016; Verloes et al., 2015). p values were computed using Fisher exact test.





A	B	C	D	L
E	F	G	M	N
H	I	O	P	Q
J	K	R	S	T

Table 1

DNA variant	Protein amino acid change	ACMG PP3 evidences	ACMG evidence levels	Family #	Familial investigation	Mode of detection
c.1189A>C	p.(Thr397Pro)	Functional assay reported previously	PS3, PM2, PP1, PP3	8	Familial	TSS
c.1246G>A	p.(Ala416Thr)	SIFT, Polyphen2, LRT, and MutationTaster: deleterious or disease-causing variant; CADD=28	PS2, PM2, PP3	7	<i>De novo</i>	TSS
c.1258G>A	p.(Glu420Lys)	SIFT, Polyphen2, LRT, and MutationTaster: deleterious or disease-causing variant; CADD=29.1. A variant in the same codon (c.1260G>C:p.Glu420Asp) previously published	PS1, PS2, PM2, PM5, PP3	2	<i>De novo</i>	WES
				4	<i>De novo</i> in pt 4-1. Present in the 2 fetuses. Absent in a normal sib.	TSS
c.1258G>A	p.(Glu420Lys)	SIFT, Polyphen2, LRT, and MutationTaster: deleterious or disease-causing variant; CADD=26.4	PM2, PP1, PP3	5	Shared by affected sisters, parents unavailable for testing	TSS
c.1382G>A	p.(Arg461Gln)	Mutation Taster, SIFT and PolyPhen2: potentially deleterious variant	PS2, PM2, PP3	3	<i>De novo</i>	WES
c.3026A>C	p.(Tyr1009Ser)	SIFT, Polyphen2, LRT, and MutationTaster: deleterious or disease-causing variant; CADD=24.9	PS2, PM2, PP1, PP3	6	Shared by proband, affected sister, and affected father. Paternal grandparents unavailable for testing.	CES
c.3293G>A	p.(Arg1098Gln)	SIFT, Polyphen2, LRT, and MutationTaster: deleterious or disease-causing variant; CADD=35	PS1, PM2, PP1 PP3	1	Present in the 4 affected patients	ES in patients 1-4 and 4-1; TSS in Relatives
			PS1, PS2, PM2, PP3	9	<i>De novo</i>	CES

Table 2

<b>Patients</b>			
Number	31		
Sex	14 males	17 females	
Mean age at last examination (for those seen after age 1)		23 years (n=16)	
<b>Growth</b>			
Birth parameters (excluding TOP)	Number	Mean	
Birth head circumference (SD)	6	-0,17	
Birth length (SD)	7	0,08	
Birth weight (SD)	9	-0,34	
Latest growth parameter (mean age: 21 years)			
Head circumference (SD)	15	-0,25	
Length (SD)	16	-1,56	
Weight (SD)	10	-1,55	
<b>Clinical features</b>	<b>Present</b>	<b>Absent</b>	<b>%</b>
Short stature	9	5	64
Prominent forehead	19	3	86
Craniosynostosis (metopic or sagittal $\pm$ coronal sutures)	3	13	19
Ocular hypertelorism	30	1	97
Palpebral ptosis	12	5	71
Widow's peak	8	14	36
High/broad nasal bridge	30	0	100
Anteverted nares	19	4	83
Long philtrum	20	1	95
Micrognathia	12	9	57
Downslanted palpebral fissures	8	10	44
Median groove of the tip of the nose	3	16	16
Posteriorly rotated ears	5	12	29
Preauricular or heliceal pits/tags	7	13	35
Cleft lip	5	26	16
Cleft palate	7	23	23
Laryngeal/tracheal anomaly (stridor, malacia...)	2	27	7
Laryngeal cleft	0	29	0
Feeding anomalies	2	12	14
Congenital heart defect (ASD, VSD and/or aortic root dilation)	6	17	26
Umbilical hernia / omphalocele	10	11	48
Diaphragmatic hernia	5	17	23
Inguinal hernia	5	12	29
Bicornuate uterus	9	0	100
Enlarged ovaries	2	3	40
Anorectal malformation	0	31	0

Urinary tract malformation	3	13	19
Hypospadias	0	14	0
Shawl scrotum	1	5	17
CNS defect (ventriculomegaly, abnormal corpus callosum)	6	3	67
Hearing loss	1	9	10
Developmental delay or learning disability (with or without ID)	11	7	61
Intellectual disability (> 2 years)	3	20	13
Autism spectrum disorder	2	11	15

Rare anomalies: thyreoglossal cyst, atresia of ear meatus, vertebral hypersegmentation (1 case each),  
natal teeth (3 cases)

Table 3

Phenotypic trait	<i>MID1</i> males	<i>MID1</i> (females)	<i>SPECC1L</i>	p value (male <i>MID1</i> vs <i>SPECC1L</i> )	BWS ( <i>ACTB</i> + <i>ACTG1</i> , combined)	p value (BWS vs <i>SPECC1L</i> )
Hypertelorism	82/82 + 27/28 = 109/110	38/42	30/31	Ns (0,39)	39/41	Ns (1)
Anteverted nares	17/25	1/42	19/23	Ns (0,49)	26/37	Ns (0,37)
Cleft lip/palate	42/85 + 14/35 = 56/120	0/42	7/30	<b>0.02</b>	8/38	Ns (1)
laryngeal defects	40/85 + 16/35 = 56/120	1/42	2/29 (0/29 laryngeal cleft)	<b>&lt;0.001</b>	0/42	Ns (0,16)
Dysphagia, reflux and other esophageal problems	31/85	2/42	4/21	Ns (0,19)	0 ?	NA
Ear pits	0/120		7/20	<b>&lt;0.001</b>	0/40	<b>&lt;0.001</b>
Heart defects	20/85 + 7/35 = 27/120	0/42	6/23	Ns (0,79)	12/36	Ns (0,58)
Omphalocele	Not reported ?		10/21	<b>&lt;0.001</b>	0/42	<b>&lt;0.001</b>
Anal defects	18/85 + 4/35 = 22/120	0/42	0/31	<b>&lt;0.001</b>	0/18	Ns (1)
Hypospadias	68/85 + 27/35 = 95/120	NA	0/14	<b>&lt;0.001</b>	0/19	Ns (1)
Uterine anomalies	NA	NA	9/9	Likely significant	NA	-
CNS malformation	3 ACC 8 hypoplasia of the vermis		6/9 (no pachygyria)	NA	37pachygyria 9 ACC	<b>&lt;0.001</b>
ID /DD	28/85 + 5/35 = 33/120	0/42	3/23	Ns (0,19)	42/42	<b>&lt;0.001</b>