



HAL
open science

Association of transcallosal motor fibres with function of both hands after unilateral neonatal arterial ischemic stroke

Samuel Groeschel, Lucie Hertz-pannier, Matthieu Delion, Sébastien Loustau, Béatrice Husson, Manoelle Kossorotoff, Cyrille Renaud, Sylvie Nguyen The Tich, Stéphane Chabrier, Mickaël Dinomais

► To cite this version:

Samuel Groeschel, Lucie Hertz-pannier, Matthieu Delion, Sébastien Loustau, Béatrice Husson, et al.. Association of transcallosal motor fibres with function of both hands after unilateral neonatal arterial ischemic stroke. *Developmental Medicine and Child Neurology*, 2017, 59 (10), pp.1042-1048. 10.1111/dmcn.13517 . hal-02510147

HAL Id: hal-02510147

<https://hal.univ-angers.fr/hal-02510147>

Submitted on 31 May 2022

HAL is a multi-disciplinary open access archive for the deposit and dissemination of scientific research documents, whether they are published or not. The documents may come from teaching and research institutions in France or abroad, or from public or private research centers.

L'archive ouverte pluridisciplinaire **HAL**, est destinée au dépôt et à la diffusion de documents scientifiques de niveau recherche, publiés ou non, émanant des établissements d'enseignement et de recherche français ou étrangers, des laboratoires publics ou privés.

Association of transcallosal motor fibres with function of both hands after unilateral neonatal arterial ischemic stroke

SAMUEL GROESCHEL¹ | LUCIE HERTZ-PANNIER² | MATTHIEU DELION³ | SÉBASTIEN LOUSTAU⁴ |
BÉATRICE HUSSON⁵ | MANOELLE KOSSOROTOFF⁶ | CYRILLE RENAUD⁷ | SYLVIE NGUYEN THE TICH⁸ |
STÉPHANE CHABRIER⁷ | MICKAEL DINOMAI⁹ | ON BEHALF OF THE AVCNN STUDY GROUP*

1 Experimental Pediatric Neuroimaging, Department of Child Neurology, University Hospital Tübingen, Tuebingen, Germany. **2** UNIACT, Neurospin, Institut Frédéric Joliot, Paris; **3** Département de neurochirurgie and Laboratoire d'anatomie, Faculté de médecine Angers, LUNAM Université d'Angers, Angers; **4** Laboratoire Angevin de Recherche en Maths (LAREMA), LUNAM Université d'Angers, Angers; **5** Pediatric Radiology Department, University Hospital Bicêtre, Assistance-Publique-Hopitaux de Paris, Paris-Sud University, Paris; **6** Paediatric Neurology Department, French Center for Paediatric Stroke, University Hospital Necker-Enfants-Malades, AP-HP, Paris; **7** CHU Saint-Étienne, Inserm, Univ Lyon, Centre national de référence de l'AVC de L'Enfant, Service de médecine physique et de réadaptation pédiatrique, Saint-Étienne; **8** Pediatric Neurology Department and Environment Périnatale et Santé, University Hospital, Lille; **9** CHU Angers, Département de Médecine Physique et de Réadaptation and LUNAM, Université d'Angers, Laboratoire Angevin de Recherche en Ingénierie des Systèmes (LARIS), Angers, France.

Correspondence to Mickael Dinomais, Département de médecine physique et réadaptation, CHU-Les Capucins, 3 rue des capucins, BP 40329, 49103 Angers Cedex 02, France.
E-mail: mickael.dinomais@les-capucins-angers.fr

ABBREVIATIONS

BBT	Box and blocks test
MCA	Middle cerebral artery
mCC	Motor part of the corpus callosum
NAIS	Neonatal arterial ischemic stroke
rCC	Rest of the corpus callosum
wCC	Whole corpus callosum

AIM The objective of this study was to investigate the involvement of the motor fibres of the corpus callosum after unilateral neonatal arterial ischemic stroke (NAIS) of the middle cerebral artery territory and the relationship to both ipsilesional and contralesional hand function.

METHOD Using high-resolution structural magnetic resonance imaging (MRI), functional MRI, and magnetic resonance diffusion-tractography, we compared the midsagittal area of the motor part of the corpus callosum (defined by the fibres connecting the precentral gyri) between 33 7-year-old children after unilateral NAIS and 31 typically developing 7-year-old children. Hand motor performance was assessed by the box and blocks test.

RESULTS Children after NAIS showed on average significantly smaller motor corpus callosum area compared to typically developing children ($p < 0.001$, without differences of the non-motor corpus callosum area). In addition, there was a significant positive association between the motor part of the corpus callosum and both contralesional ($\text{Pr}(>|t|) = 0.034$) and ipsilesional hand motor performance ($\text{Pr}(>|t|) = 0.006$) after controlling for lesion volume and sex. In a post-hoc analysis the additional contribution of corticospinal tract damage was evaluated.

INTERPRETATION Compared to typically developing children, children after NAIS exhibited a smaller motor part of their corpus callosum associated with reduced contralesional but also ipsilesional manual dexterity. These results indicate that the affection of transcallosal motor fibres in unilateral NAIS might be of functional relevance and an important part of the involved structural network that should be elucidated in further studies.

The corpus callosum is the largest white matter pathway in the brain connecting bi-directionally homotopic cortical areas between the two hemispheres. The motor part of the corpus callosum can be defined as the part connecting the primary motor areas (M1) in the precentral gyri¹ and is important for unimanual and bimanual motor performance through inhibitory and excitatory effects.^{2,3} Although the association between structural integrity of the corpus callosum and motor performance has been demonstrated in adults with stroke,^{4,5} this relationship remains unexplored

in children after unilateral neonatal arterial ischemic stroke (NAIS).

Neuroimaging data showed that unilateral early brain injury can lead to different patterns of motor system reorganization depending on the type and time of lesion occurrence.^{6,7} Patients with prenatal or perinatally acquired unilateral lesions to either the motor cortex or the corticospinal tract may develop ipsilateral corticospinal pathways, which allow the unaffected hemisphere to control the paretic hand (ipsilateral reorganization of motor

control). The presence of mirror movements reflects this interhemispheric reorganization.⁸ This type of interhemispheric reorganization is often observed following unilateral periventricular brain lesions,⁸ but can also be observed less often following perinatal ischemic stroke.⁹

Models for understanding developmental neuroplasticity of the motor system after early unilateral lesions suggest interactions between the ipsilesional and contralesional motor cortex¹⁰ as the key to clinical function, but the structural connection between the motor cortices (i.e. the corpus callosum) remains an understudied element of such models. The same models have also recently been translated in positive neuromodulation clinical trials, suggesting high translational relevance.^{11,12} NAIS represents ‘an ideal human model’ for understanding developmental motor plasticity.¹³ Having more mechanistic studies on how the two motor cortices structurally interact could add more knowledge on how to design ‘advance personalized’ neuromodulation therapies for children having suffered from NAIS.¹²

An association between the size of the corpus callosum and the motor performance of both hands after early unilateral brain lesions would support the importance of the corpus callosum for bilateral motor performance. In this work, we examined the relationship between structural changes of the corpus callosum, especially of its motor part, and the motor performance of both hands after unilateral NAIS.

METHODS

Participants

As part of the AVCnn study,^{14,15} 33 7-year-old children (13 females, 20 males; mean age 7y 3mo [SD 2.46mo], range 6y 11mo–7y 11mo) with a history of unilateral NAIS of the middle cerebral artery (MCA) territory participated in a follow-up investigation with 3T magnetic resonance imaging (MRI) and motor evaluation. The participants in this study were the same as in our previous study,^{16,17} except for five participants where neither diffusion-weighted imaging nor box and blocks test (BBT, see below) data were available. The recruitment criteria of the participants were given in more details in the previous cohort description.^{14–18} Further sample characteristics are presented in Table I.

Motor performance of the ipsilesional and contralesional hands was assessed with the BBT, a reliable and validated tool for measuring gross manual dexterity in children.¹⁹ For each child after NAIS, the maximum number of cubes was defined that were transferred by the ipsilesional and the contralesional hand from one compartment to the other in one minute.

The presence of mirror movements was also assessed⁸ using video-recorded examination. Children after NAIS exhibiting contralateral involuntary finger movements that were reproducible, phasic, and exceeding the amplitude of 10mm at the fingertips during voluntary unimanual movements (repetitive fist clenching, repetitive index finger-to-

What this paper adds

- Unilateral neonatal arterial ischemic stroke (NAIS) in middle cerebral artery territory affects transcallosal motor fibres.
- Affection of transcallosal motor fibres after NAIS is associated with both contralesional and ipsilesional gross manual dexterity as assessed by box and block test.
- Unilateral lesions in the developing brain may influence dexterity of both hands through involvement of corpus callosum.

thumb opposition, and sequential finger-to-thumb opposition) were considered having mirror movements. This definition of mirror movements⁸ corresponds to grades 3 to 4 (i.e. 3=strong and unsustained repetitive movement, 4=movement equal to that performed by the intended hand) in the criteria proposed by Woods and Teuber.²⁰

In addition, MRI data of a control group of 31 typically developing children were acquired, who had no neurological history and normal neurological examination (17 males, 14 females; mean age 7y 8mo [SD 6.88 mo], range 6y 9mo–8y 9mo).

Written informed consent from typically developing children/patients/parents was obtained and the study protocol was approved by the local Ethics Committee (eudract-number-2010-A00976-33).

MRI acquisition and processing

All images were acquired on the same 3.0 Tesla scanner (Siemens Trio, 12-channel head coil, at Neuropsin-CEA-Saclay, France).

As described before,^{16,17} a high-resolution 3D T1-weighted image was obtained covering the whole brain (176 sagittal slices, repetition time 2300ms, echo time 4.18ms, field of view 256mm, flip angle=9°, voxel size 1×1×1mm³) as well as a diffusion-weighted dual spin-echo planar imaging sequence with 30 diffusion-weighted directions and a diffusion-weighting of b=1000s/mm² (repetition time 9500ms, echo time 86ms, 40 slices, voxel size 1.875×1.875×3mm³). Diffusion-weighted images were processed using the MRtrix software package²¹ (www.mrtrix.org), reconstructing the transcallosal motor pathways using probabilistic tractography based on constrained spherical deconvolution.²²

Functional localization of primary motor cortices (M1s)

Functional MRI (fMRI) was used for functional identification of both M1s (for tractography of transcallosal fibres). An echo planar imaging sequence was used to acquire functional series (repetition time 2500ms, echo time 30ms, 40 axial sequential slices of 3.0mm slice thickness, in plane matrix=64×64, yielding a voxel size of 3×3×3mm³), with 60 functional volumes per session.

The fMRI paradigm was implemented in block design (first practised by the child in a mock scanner) with two conditions (20s each, repeated 5 times), checked and video recorded during the acquisition: (1) repetitive hand opening and closing at a frequency of 1Hz (=motor task condition, guided by 1Hz metronome sounds over headphones); (2) rest condition. Two identical functional sessions were

Table 1: Sample characteristics and individual results for hand motor function, measurements of corpus callosum, and lesion volumes

No.	Sex	Motor examination	Handedness	Lesion side	Contralesional BBT	Ipsilesional BBT	Ratio mCC	Ratio rCC	Ratio wCC	Lesion volume
2	M	L hemi	R	R	25	36	0.00292	0.03309	0.03601	140.644
3	M	N	L	L	22	28	0.00486	0.02474	0.02960	21.824
4	M	N	R	R	25	31	0.00445	0.03309	0.03754	34.348
5	M	N	L	L	44	42	0.00602	0.04905	0.05507	35.483
6	F	N	R	L	30	30	0.00345	0.03150	0.03495	3.377
7	F	N	R	R	23	23	0.00390	0.04039	0.04429	10.956
8	M	L hemi	R	R	19	24	0.00335	0.02169	0.02504	42.55
9	F	N	R	L	28	25	0.00324	0.02841	0.03165	38.398
10	F	L hemi	R	R	26	34	0.00301	0.03008	0.03309	83.812
11	M	N	R	L	39	29	0.00343	0.03630	0.03973	0.293
12	F	L hemi	R	R	22	31	0.00373	0.03121	0.03494	127.433
13	M	N	L	L	26	25	0.00352	0.02914	0.03265	1.924
14	F	N	R	R	28	31	0.00353	0.02989	0.03342	10.128
15	M	N	R	L	28	31	0.00401	0.03150	0.03551	48.26
16	F	N	L	L	43	41	0.00468	0.03026	0.03494	0.686
17	M	N	R	R	33	33	0.00416	0.03097	0.03513	2.935
18	F	N	L	L	30	40	0.00412	0.03341	0.03753	84.98
19	M	N	R	L	38	34	0.00330	0.03136	0.03467	2.982
20	M	N	R	R	39	33	0.00425	0.03234	0.03659	14.321
21	F	N	L	L	29	34	0.00312	0.02791	0.03103	23.923
23	M	N	R	R	28	34	0.00472	0.03214	0.03686	15.072
24	M	R hemi	L	L	10	26	0.00220	0.02781	0.03002	181.779
25	M	N	L	L	37	42	0.00501	0.03716	0.04216	31.116
26	M	R hemi	L	L	31	34	0.00348	0.03344	0.03692	123.848
27	F	N	R	R	31	39	0.00463	0.03843	0.04306	1.027
28	M	R hemi	L	L	40	42	0.00440	0.03005	0.03445	69.073
29	F	R hemi	L	L	14	17	0.00438	0.03775	0.04213	8.597
30	M	N	L	R	44	44	0.00466	0.03539	0.04005	0.652
31	F	N	R	L	31	35	0.00552	0.03452	0.04004	19.284
32	F	R hemi	L	L	17	27	0.00328	0.03254	0.03582	76.038
34	M	R hemi	L	L	4	28	0.00315	0.03409	0.03724	8.905
35	M	N	R	R	31	31	0.00464	0.03449	0.03912	1.698
36	M	L hemi	R	R	22	28	0.00272	0.03987	0.04259	76.786

Participant numbers correspond to Table I in Dinomais et al.¹⁶ F, female; M, male; R, right; L, left; N, normal; hemi, hemiplegia; contraBBT, box and blocks test score for the contralesional hand; ipsiBBT, box and blocks test score for the ipsilesional hand; mCC, motor part of the corpus callosum; rCC, rest of the corpus callosum; wCC, whole corpus callosum.

performed, one for each hand. fMRI during active motor tasks may indicate shift in M1 activation toward the unaffected hemisphere when moving the paretic hand.²³ The acquisition was successful in 29 out of 33 children after NAIS and in 30 out of 31 typically developing children.

Single-subject fMRI analysis²⁴ was done using standard functionality in the SPM8 software (www.fil.ion.ucl.ac.uk/spm) running in Matlab R2011a (MathWorks, Natick, USA). A statistical parametric map was calculated for each participant and for each hand using the framework of the general linear model (significance $p < 0.001$ uncorrected).

Each participant's 3D-T1-weighted image and fMRI activation maps were co-registered to the individual fractional anisotropy (FA) image using FSL FLIRT tool (<http://fsl.fmrib.ox.ac.uk/fsl/fslwiki/FSL>)²⁵

Corpus callosum delineation and measurements

To identify the motor fibres connecting primary motor areas, the precentral gyri were defined anatomically as described before,²⁶ using overlaid anatomical and FA images with additional confirmation by fMRI activation of the hand motor paradigm as described above.²⁶ The transcallosal motor fibres were projected on to the co-registered 3D-T1-weighted images to identify the voxels

containing the motor part of the corpus callosum (=mCC), indicated in Figure 1. Both the mCC and the whole corpus callosum (=wCC) areas were measured manually in the midsagittal plane (defined as the medial plane, including the third ventricle, after analysis on the three planes) by consensus of two expert raters blinded to clinical information (Fig. 1),¹⁶ using ITK-SNAP software (www.itk-snap.org).²⁷ In addition, the total intracranial (midsagittal) area was measured to correct for the variability of brain size across participants. Hence, final mCC and wCC were normalized by brain size (ratio). The rest of the corpus callosum (=rCC) was calculated as follows: $rCC = wCC - mCC$.

Measuring the midsagittal areas of the transcallosal fibres using high-resolution 3D T1-weighted images (1mm slice thickness) rather than diffusion tensor imaging parameters (3mm slice thickness) has the great advantage of reducing partial volume effects from cerebrospinal fluid contamination of the ventricles, especially in case of corpus callosum atrophy in children after NAIS^{28,29} and therefore making the results more meaningful. It would be almost impossible to disentangle those partial volume effects from real changes in diffusivity when interpreting changes in FA, diffusion tensor imaging (DTI) eigenvalues, or mean diffusivity in a thin structure like the corpus callosum with

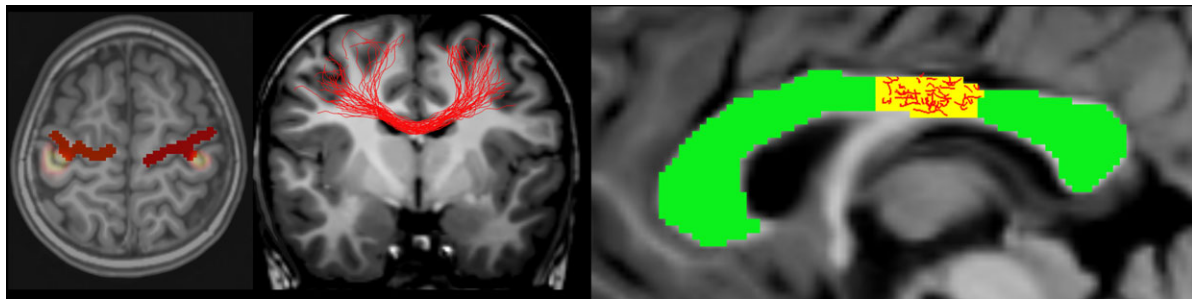


Figure 1: Constrained-spherical, deconvolution-based probabilistic tractography was used to identify the transcallosal motor fibres (in red) connecting the primary motor cortex (middle), which was delineated anatomically as described previously.²⁶ In addition, functional magnetic resonance imaging activation of hand movements was used as additional guidance for identification of the precentral gyri. The midsagittal area of the corpus callosum (green) and its motor part (yellow, as defined by the transcallosal fibres) were traced manually. [Colour figure can be viewed at wileyonlinelibrary.com].

additional atrophy, given the relatively low-resolution, diffusion-weighted data.^{26,29}

Statistics

Area measurements (mCC, rCC, and wCC) were compared between children after NAIS and typically developing children using a parametric unpaired *t*-test.

A linear model (analysis of covariance [ANCOVA]) was conducted to determine the relationship between the BBT scores (separately for ipsilesional and contralesional hand) and cross-sectional areas of the corpus callosum (mCC and rCC) controlling for lesion volume (obtained from our previous work)¹⁶ and sex, see Table I. The principal assumptions of a linear model are the independence, normality, and the homoscedasticity of the error, which were tested over the residuals (and found to hold true). Lesion volume and sex were put as nuisance covariables in our statistical model due their possible influence on motor outcomes following NAIS.³⁰

Exact levels of significance are reported. A *p*-value of less than 0.05 was considered statistically significant. All statistical analyses were performed using R (www.r-project.org).

Post-hoc analysis of correlation with corticospinal tract

To assess the additional involvement of the corticospinal tract in hand motor function after NAIS, we correlated DTI values (for both ipsilesional and contralesional side) at

the level of the posterior limb of the internal capsule with the BBT scores using Pearson correlation coefficient. The DTI values were calculated as part of our previous work,¹⁶ where the corticospinal tract was delineated using probabilistic tractography and the measurement region in the posterior limb of the internal capsule was extracted using equally distributed levels along the tract.

RESULTS

Midsagittal area of corpus callosum (Fig. 2)

The area of wCC was smaller in children after NAIS (mean 0.03678 [SD 0.005365], 95% confidence interval [CI] 0.03488–0.03869) than in typically developing children (mean 0.04048 [SD 0.004016], 95% CI 0.03901–0.04196, *p*=0.029). When focusing on the motor part of the corpus callosum, mCC was on average clearly smaller in children after NAIS (mean 0.003934 [SD 0.0008429], 95% CI 0.003636–0.004233) than in typically developing children (mean=0.005867, SD 0.0008010, 95% CI 0.005574–0.006161, *p*<0.001), and the difference between the two groups was more pronounced (*p*<0.001) than for wCC (*p*=0.029).

By contrast, there was no statistical difference between the two groups concerning the rCC (mean 0.004 [SD 0.001], 95% CI 0.004 for NAIS; mean 0.03462 [SD 0.003667], 95% CI 0.03327–0.03596 for typically developing children, *p*=0.11).

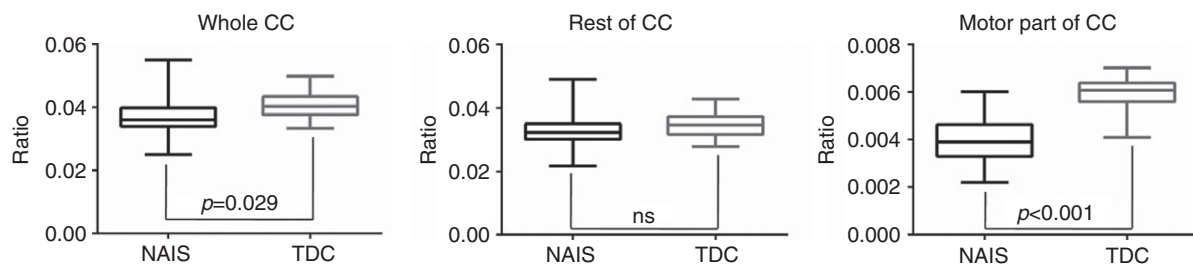


Figure 2: Box and whisker plots displaying comparisons of cross-sectional corpus callosum (CC) areas between the two groups (children after neonatal arterial ischemic stroke [NAIS] and typically developing children [TDC]). ns: non-significant.

Hand motor performance and corpus callosum

The mean BBT scores for the contralesional hand were 28.39 cubes per minute (SD 9.40; 95% CI of mean: 25.06–31.73) and for the ipsilesional hand 32.18 cubes per minute (SD 6.32; 95% CI 29.94–34.42). Only two participants (2/33, 6% of our sample, participants #24 and #34) exhibited mirror movements.

In children after NAIS, the ANCOVA analysis ($F(4, 28) = 3.062, p = 0.033$) showed a positive association between the BBT score of the contralesional hand and mCC area ($t = 2.233, \Pr(>|t|) = 0.034$) by contrast to rCC area ($t = 0.304, \Pr(>|t|) = 0.76$) after controlling for lesion volume ($t = -0.784, \Pr(>|t|) = 0.44$) and sex ($t = 0.657, \Pr(>|t|) = 0.52$). The Durbin–Watson test ($DW = 2.2354, p = 0.80$) showed absence of autocorrelation of the residuals.

The ANCOVA analysis ($F(4, 28) = 2.903, p = 0.040$) also found a positive association between the BBT score of the ipsilesional hand and mCC area ($t = 2.954, \Pr(>|t|) = 0.0063$) but not with rCC area ($t = 0.217, \Pr(>|t|) = 0.83$) after controlling for lesion volume ($t = 1.491, \Pr(>|t|) = 0.15$) and sex ($t = 0.467, \Pr(>|t|) = 0.64$). The Durbin–Watson test ($DW = 2.4198, p = 0.92$) again dismissed correlation of the residuals.

Hand motor performance and corticospinal tract

There was a significant positive correlation of the ipsilesional corticospinal tract with the contralesional hand function (contralesional BBT scores with FA $r = 0.41 [p = 0.017]$, negative correlations with apparent diffusion coefficient (ADC) $r = -0.46 [p = 0.007]$, with radial $r = -0.45 [p = 0.009]$, and axial diffusivity $r = -0.46 [p = 0.007]$), but no significant correlation ($p > 0.1$) with ipsilesional BBT scores. In addition, the contralesional corticospinal tract did not show a significant correlation of FA and eigenvalues with the ipsilesional BBT scores, only the ADC values were negatively correlated ($r = -0.46, p = 0.008$). Also, there was no significant correlation of contralesional corticospinal tract values with contralesional BBT scores ($p > 0.1$).

To investigate whether the corticospinal tract damage of the ipsilesional corticospinal tract correlates with the mCC damage as expected due to their same anatomical origin (MCA stroke territory), we correlated the mCC area with corticospinal tract results in the posterior limb of the internal capsule. We found significant positive correlation (Pearson's $r = 0.40 [p = 0.001]$) for FA and negative correlations (Pearson's $r = -0.42$ for ADC [$p = 0.001$], $r = -0.38$ for radial diffusivity [$p < 0.01$], and $r = -0.48$ for axial diffusivity [$p < 0.001$]).

DISCUSSION

The present study underlines the importance of the motor part of the corpus callosum for bilateral hand motor function after unilateral NAIS. During movement, activity of one M1 is modulated by the activity of the opposite M1 through inhibitory and/or excitatory effects transmitted by motor transcallosal fibres.² The structural integrity of these fibres is hereby crucial for the interhemispheric exchange

of neurophysiological signalling and associated with the motor performance of both sides of the human body.³¹ The current study further supports the importance of these interhemispheric interactions for motor function through transcallosal motor fibres after early brain lesions, in line with earlier studies in adults with stroke.^{4,5}

Early injury to the developing white matter leads to structural changes of the corpus callosum in children with periventricular leukomalacia, a major form of preterm brain injury,^{32,33} which were related to gross motor function.³⁴ Furthermore, the reduction in size of the corpus callosum was associated with poor motor performance in children with neonatal encephalopathy.³⁵ Our study shows that early unilateral focal lesions, also affecting grey matter, have an impact on white matter structures remotely from the primary infarct later during childhood, with long lasting functional consequences.

The size reduction of the motor part of the corpus callosum in children after NAIS might relate to secondary axonal degeneration following the primary ischemic neuronal cell body damage and resulting in a loss of transcallosal motor fibres (diminution of axon density) and/or subsequently reduced myelin thickness. Interestingly, corpus callosum area measurements have been associated with axon density.³⁶ In the acute phase after NAIS, pre-Wallerian degeneration of axons remote from the infarct site has been demonstrated in the corticospinal tract,^{14,17} visible as a reduced ADC on diffusion imaging, often followed by peduncular atrophy, both being highly predictive of the further development of unilateral cerebral palsy. Similar to the corticospinal tract, the reduced size of the mCC might result from Wallerian degeneration.

The association between focal grey matter injuries and the topographic distribution of Wallerian degeneration in the corpus callosum has been described previously.³⁷ In this (historical) post-mortem study, the authors showed degeneration of the motor part of the corpus callosum in case of cortical lesions located in the MCA territory. Our finding of the selective involvement of the motor part of the corpus callosum in the case of NAIS in the MCA territory confirms the early findings,³⁷ in line with the topography of the corpus callosum with axons traversing the corpus callosum to their (cortical) origin.³⁸

Our finding that the ipsilesional corticospinal tract damage correlated with the involvement of transcallosal motor fibres underlines that unilateral NAIS in MCA territory damages a broader structural network including fibres of both the corticospinal tract and the mCC, probably due to the location of the infarct. The damage of the ipsilesional structural corticospinal tract might be related more directly to the contralesional hand motor dysfunction in these children;¹⁶ whereas the involvement of the transcallosal motor fibres (mCC) could be responsible for the ipsilesional hand motor dysfunction, with only marginal contribution of the contralesional corticospinal tract. For children with reorganization of motor control to the contralesional hemisphere (ipsilateral motor reorganization), the contribution of the

contralesional corticospinal tract in the ipsilesional hand motor function could be more important. Further studies are needed to test this in this sub-population.

While reporting an association between transcallosal motor fibres and hand motor function, it is of importance to keep in mind that with our study design we could not prove causality, nor did we investigate the extended structural network of fibre pathways known to be involved in hand motor dysfunction after unilateral NAIS. Such network analyses would require a whole-brain structural analysis and additional neurophysiological measures in order to understand potential causal effects.¹¹ Using fMRI, however, we were able to add more information about the functional motor network in our cohort, demonstrating that M1 functional localization remained in the affected hemisphere in all patients but one (participant #24) who had unilateral cerebral palsy (and mirror movements) and where fMRI peak activation following paretic hand movement was located in the precentral gyrus of the unaffected hemisphere. Note that participant #34 also exhibited mirror movements, but that fMRI peak activation following paretic hand movement was in the precentral gyrus of the affected hemisphere. No other patients showed clinical or neuroimaging evidence of reorganization of motor control to the unaffected hemisphere (ipsilateral reorganization), with the known limitation that active motor fMRI tasks also partly activate the primary somatosensory area by afferent somatosensory information. However, removing the two participants from our analysis did not change the significance of results in our study. Regarding the statistical method used here, it must be noted that due to the historical follow-up cohort (AVCnn study), no a priori power calculation has been done. Still, our very homogenous cohort of participants with this rare condition reduces (e.g. age-related) between-subject variability and suggests the observed effect to be valid and relevant, also given the relatively small sample size.³⁹

Our results have further important clinical and methodological implications. When assessing a child after unilateral NAIS in clinical practice or in a research setting, both the contralesional and the ipsilesional hands should be evaluated. And, even more importantly, in future

therapeutic trials for children with unilateral hemiparesis following NAIS (e.g. using transcranial direct current stimulation)¹² the target could not only be the contralesional primary motor cortex, but as well its supposedly non-damaged counterpart of the ipsilesional hemisphere. The same remark holds true for the type of noninvasive neuromodulation used (i.e. inhibitory or excitatory stimulation).

CONCLUSION

After NAIS, contralesional hand motor performance is related not only to structural abnormalities of the ipsilesional grey matter and connected white matter structures^{16,17} but also to changes in transcallosal motor fibres. Interestingly, the changes in this part of the corpus callosum also influence motor performance of the ipsilesional hand. Therefore, early unilateral brain lesions influence the motor performance of both hands during childhood. This study thus underlines that unilateral NAIS is a focal early brain injury with global structural effects on the developing brain by influencing brain structures remote from the infarct.

ACKNOWLEDGEMENTS

The research was supported by the University Hospital of Angers (eudract-number-2010-A00976-33), the University Hospital of Saint-Étienne (eudract-number-2010-A00329-30), and the Fondation de l'Avenir (ET0-571). Sponsors of the study had no role in the study design data collection, data analysis, data interpretation, writing of the report, or decision to submit for publication. The corresponding author had full access to all the data in the study and had final responsibility for the decision to submit for publication. Trial registration numbers: PHRC régional no. 0308052 and PHRC interrégional no. 1008026; EudraCT number 2010-A00329-30; ClinicalTrials.gov Identifier: NCT02511249. The authors have stated that they had no interests that might be perceived as posing a conflict or bias.

SUPPORTING INFORMATION

The following additional material may be found online:

Appendix S1: AVCnn Group members.

REFERENCES

1. Hofer S, Frahm J. Topography of the human corpus callosum revisited – comprehensive fiber tractography using diffusion tensor magnetic resonance imaging. *NeuroImage* 2006; **32**: 989–94.
2. Wahl M, Ziemann U. The human motor corpus callosum. *Rev Neurosci* 2008; **19**: 451–66.
3. Gooijers J, Swinnen SP. Interactions between brain structure and behavior: the corpus callosum and bimanual coordination. *Neurosci Biobehav Rev* 2014; **43**: 1–19.
4. Li Y, Wu P, Liang F, Huang W. The microstructural status of the corpus callosum is associated with the degree of motor function and neurological deficit in stroke patients. *PLoS ONE* 2015; **10**: e0122615.
5. Wang LE, Tittgemeyer M, Imperati D, et al. Degeneration of corpus callosum and recovery of motor function after stroke: a multimodal magnetic resonance imaging study. *Hum Brain Mapp* 2012; **33**: 2941–56.
6. Holmstrom L, Vollmer B, Tedroff K, et al. Hand function in relation to brain lesions and corticomotor-projection pattern in children with unilateral cerebral palsy. *Dev Med Child Neurol* 2010; **52**: 145–52.
7. Staudt M. Reorganization after pre- and perinatal brain lesions. *J Anat* 2010; **217**: 469–74.
8. Staudt M, Grodd W, Gerloff C, Erb M, Stitz J, Kragehlo-Mann I. Two types of ipsilateral reorganization in congenital hemiparesis: a TMS and fMRI study. *Brain* 2002; **125**: 2222–37.
9. van der Aa NE, Verhage CH, Groenendaal F, et al. Neonatal neuroimaging predicts recruitment of contralesional corticospinal tracts following perinatal brain injury. *Dev Med Child Neurol* 2013; **55**: 707–12.

10. Juenger H, Koerte IK, Muehlmann M, et al. Microstructure of transcallosal motor fibers reflects type of cortical (re-)organization in congenital hemiparesis. *Eur J Paediatr Neurol* 2014; **18**: 691–7.
11. Zewdie E, Damji O, Ciechanski P, Seeger T, Kirton A. contralesional corticomotor neurophysiology in hemiparetic children with perinatal stroke: developmental plasticity and clinical function. *Neurorehabil Neural Repair* 2017; **31**: 261–71.
12. Kirton A, Ciechanski P, Zewdie E, et al. Transcranial direct current stimulation for children with perinatal stroke and hemiparesis. *Neurology* 2017; **88**: 259–67.
13. Kirton A, Deveber G. Life after perinatal stroke. *Stroke* 2013; **44**: 3265–71.
14. Husson B, Hertz-Pannier L, Renaud C, et al. Motor outcomes after neonatal arterial ischemic stroke related to early MRI data in a prospective study. *Pediatrics* 2010; **126**: 912–8.
15. Chabrier S, Saliba E, Nguyen The Tich S, et al. Obstetrical and neonatal characteristics vary with birthweight in a cohort of 100 term newborns with symptomatic arterial ischemic stroke. *Eur J Paediatr Neurol* 2010; **14**: 206–13.
16. Dinomais M, Hertz-Pannier L, Groeschel S, et al. Long term motor function after neonatal stroke: lesion localization above all. *Hum Brain Mapp* 2015; **36**: 4793–807.
17. Dinomais M, Hertz-Pannier L, Groeschel S, et al. Does contralesional hand function after neonatal stroke only depend on lesion characteristics? *Stroke* 2016; **47**: 1647–50.
18. Chabrier S, Peyric E, Drutel L, et al. Multimodal outcome at 7 years of age after neonatal arterial ischemic stroke. *J Pediatr* 2016; **172**: 156–61 e3.
19. Mathiowetz V, Federman S, Wiemer D. Box and block test of manual dexterity: norms for 6–19 years olds. *Can J Occup Ther* 1985; **52**: 241–5.
20. Woods BT, Teuber HL. Mirror movements after childhood hemiparesis. *Neurology* 1978; **28**: 1152–7.
21. Tournier JD, Calamante F, Connelly A. MRtrix: diffusion tractography in crossing fiber regions. *Int J Imaging Syst Technol* 2012; **22**: 53–66.
22. Tournier JD, Calamante F, Connelly A. Robust determination of the fibre orientation distribution in diffusion MRI: non-negativity constrained super-resolved spherical deconvolution. *NeuroImage* 2007; **35**: 1459–72.
23. Mackey A, Stinear C, Stott S, Byblow WD. Upper limb function and cortical organization in youth with unilateral cerebral palsy. *Front Neurol* 2014; **5**: 117.
24. Fadiga L. Functional magnetic resonance imaging: measuring versus estimating. *NeuroImage* 2007; **37**: 1042–4; discussion 66–8.
25. Jenkinson M, Bannister P, Brady M, Smith S. Improved optimization for the robust and accurate linear registration and motion correction of brain images. *NeuroImage* 2002; **17**: 825–41.
26. Groeschel S, Tournier JD, Northam GB, et al. Identification and interpretation of microstructural abnormalities in motor pathways in adolescents born preterm. *NeuroImage* 2014; **87**: 209–19.
27. Yushkevich PA, Piven J, Hazlett HC, et al. User-guided 3D active contour segmentation of anatomical structures: significantly improved efficiency and reliability. *NeuroImage* 2006; **31**: 1116–28.
28. Jones DK, Cercignani M. Twenty-five pitfalls in the analysis of diffusion MRI data. *NMR Biomed* 2010; **23**: 803–20.
29. Vos SB, Jones DK, Viergever MA, Leemans A. Partial volume effect as a hidden covariate in DTI analyses. *NeuroImage* 2011; **55**: 1566–76.
30. Golomb MR, Garg BP, Saha C, Azzouz F, Williams LS. Cerebral palsy after perinatal arterial ischemic stroke. *J Child Neurol* 2008; **23**: 279–86.
31. Fling BW, Seidler RD. Fundamental differences in callosal structure, neurophysiologic function, and bimanual control in young and older adults. *Cereb Cortex* 2012; **22**: 2643–52.
32. Hoon AH Jr, Lawrie WT Jr, Melhem ER, et al. Diffusion tensor imaging of periventricular leukomalacia shows affected sensory cortex white matter pathways. *Neurology* 2002; **59**: 752–6.
33. Koerte I, Pelavin P, Kirmess B, et al. Anisotropy of transcallosal motor fibres indicates functional impairment in children with periventricular leukomalacia. *Dev Med Child Neurol* 2011; **53**: 179–86.
34. Davatzikos C, Barzi A, Lawrie T, Hoon AH Jr, Melhem ER. Correlation of corpus callosal morphometry with cognitive and motor function in periventricular leukomalacia. *Neuropediatrics* 2003; **34**: 247–52.
35. Van Kooij BJ, Van Handel M, Uiterwaal CS, et al. Corpus callosum size in relation to motor performance in 9- to 10-year-old children with neonatal encephalopathy. *Pediatr Res* 2008; **63**: 103–8.
36. Evangelou N, Konz D, Esiri MM, Smith S, Palace J, Matthews PM. Regional axonal loss in the corpus callosum correlates with cerebral white matter lesion volume and distribution in multiple sclerosis. *Brain* 2000; **123**: 1845–9.
37. de Lacoste MC, Kirkpatrick JB, Ross ED. Topography of the human corpus callosum. *J Neuropathol Exp Neurol* 1985; **44**: 578–91.
38. Lebel C, Caverhill-Godkewitsch S, Beaulieu C. Age-related regional variations of the corpus callosum identified by diffusion tensor tractography. *NeuroImage* 2010; **52**: 20–31.
39. Friston K. Ten ironic rules for non-statistical reviewers. *NeuroImage* 2012; **61**: 1300–10.